



Naif Arab University for Security Sciences
Arab Journal of Forensic Sciences & Forensic Medicine

المجلة العربية لعلوم الأدلة الجنائية والطب الشرعي
<https://journals.nauss.edu.sa/index.php/AJFSFM>



Suicidal Cut-throat Fatalities: A Case Report from the Kingdom of Bahrain

حالات وفيات الانتحار بذيح العنق: تقرير حالة من مملكة البحرين

Mohammed N. E. Fouda *, Aqeela S. Abuidrees

Forensic Medicine Department, Directorate of Forensic Science Evidence, Public Prosecution, Kingdom of Bahrain

Received 03 Oct. 2019; Accepted 31 May. 2020; Available Online 07 Sep. 2020



CrossMark

Abstract

Using a sharp tool by an individual to cause a severe cut-throat injury is considered an unusual method for suicide. Investigating such suicidal cases is challenging, as no witness is available only the crime scene findings, the autopsy finding and the history of the victim. In this case report, we demonstrate a rare suicidal case received by the directorate of forensic science evidence in the Kingdom of Bahrain.

A 39-year-old male was found with a neck laceration in his house, a small knife was found near his body, autopsy showed a cut-throat injury almost completely encircling the neck. Multiple superficial wounds were found in the proximity and parallel to the large incised wound in the front and back of the neck suggesting that they were hesitation marks. A stab wound was found directly medial to the left nipple. The final report was based on death scene investigation, autopsy findings and forensic laboratory results concluding that the death was suicidal in nature.

المستخلص

يعد استخدام آلة حادة لنحر العنق من الحالات النادرة في قضايا الانتحار، حيث يعتبر التحقيق في هذا النوع من القضايا من التحديات الكبيرة في مجال الطب الشرعي لغياب الشهود والاقتصاص على ما يتحصل عليه من مسرح الجريمة وتشريح الجثة والتاريخ الصحي للمتوفى فقط. في هذا المقال نعرض حالة نادرة تعاملت معها إدارة الأدلة الجنائية التابعة للنيابة العامة بمملكة البحرين، حيث تم العثور على رجل يبلغ من العمر 39 عاماً مذبوحوماً في منزله، وعثر على سكين صغير بالقرب منه، وقد أظهر إجراء الصفة التشريحية وجود جرح قطعي غائر ملتف تقريباً حول كامل الرقبة كما تم العثور على جروح سطحية متعددة على مقربة ومتوازية مع الإصابة سالفة الذكر في الجزء الأمامي والخلفي من العنق؛ مما يشير إلى أنها علامات تردد، إضافة إلى الجروح السابقة تم العثور على إصابة طفعية بالقرب من الحلمة اليسرى. وقد كانت النتيجة النهائية وبناء على التحقيق في مسرح الوفاة وتشريح الجثة ونتائج المختبرات الجنائية تشير إلى أن الوفاة كانت انتحارية بطبيعتها.

Keywords: Forensic Science, Forensic Medicine, Cut throat injuries, DNA profiling, Forensic Toxicology.

الكلمات المفتاحية: علوم الأدلة الجنائية، الطب الشرعي، الجرح القطعي في العنق، التسميط الوراثي، السموم الجنائي.



Production and hosting by NAUSS



* Corresponding Author: Mohammed Nour Eldin Fouda

Email: M.Nour@ppb.gov.bh; nouropan@yahoo.com

doi: [10.26735/WGBV2621](https://doi.org/10.26735/WGBV2621)

1. Introduction

The differentiation between homicidal, suicidal, and accidental cause of death is a subject of debate and challenge for many forensic medical examiners. Differing geographical regions play a significant role in forming different patterns and methods of suicide due to varying culture, religion, and social values [1]. According to the WHO, hanging is considered the leading method of suicide in the world [2]. A study performed in Kuwait also concluded that the most common method of suicide in Kuwait and in the Middle East is hanging as many of these countries share similar social and cultural parameters with Kuwait [3].

Incised wounds of the neck can be accidental, homicidal, or suicidal. Accidental wounds commonly occur at home or in a workshop. The typical findings at the scene of death should make the matter obvious that how the act occurred. There will be blood marks on the cutting edge and a trail of blood droplets leading to the body which is likely to lie a distance from the primary location. Incision wounds are usually at the front of the neck. Incised wounds intended for suicide are typically multiple, often being characterized by a number of preliminary trial cuts called ‘tentative incisions’ (hesitation marks). The classical description of a throat-cutting suicide is of incisions starting high on the one side of the neck below the angle of the jaw, passing obliquely across the front of the neck to the end on the other side [4]. Homicidal cut-throat injuries are usually single, located over the lower part of the neck and associated with the transection of carotid arteries and vital structures within the neck resulting in arterial bleeding leading to death [5]. Some reported cases show atypical cut-throat injuries, both in suicidal and homicidal nature, as absence of hesitation cuts in suicidal deaths and presence of multiple superficial wounds near the incision wounds in homicidal wounds. Most reported cases of cut-throat deaths are inflicted by using knives with exception to accidental injuries where the inflicting instruments vary depending on the available instruments in the vicinity of the victim such as chainsaws or broken glass [5, 6].

The recognition of the manner of death in throat-cutting cases either homicidal, suicidal or accidental is considered a difficult mission for the forensic medical examiner. Collective data of the medical history of the victim, psychiatric history, crime scene findings and autopsy findings will lead the medical examiner and investigations to better conclusions of the cause of death [7].

This report discusses a rare case of a fatal throat-cutting death that was presented to the department of forensic medicine and shows the integration of forensic

findings from the autopsy, death scene investigation and laboratory tests that collectively helped the investigators in reaching a final conclusion that it was a suicidal death case.

2. The Case

A case was submitted to the directorate of forensic science evidence stating that a dead body of a 39-year-old single unemployed male was found in his house, with a neck laceration, a small knife was found close to his body. His family members were questioned, and they stated that the deceased was a psychiatric patient who was treated in a psychiatric hospital as a patient of severe depression. He was usually alone and the previous night he entered his room and locked the door. In the morning the family members knocked on the door with no response so they used force to open the door and upon entry they found the person lying on the floor gasping for air, his neck was cut, they thought that he cut his neck using a knife. Emergency rescue paramedics were called on the site but upon arrival declared him dead on arrival at the scene.

2.1. Death Scene Examination

The house where the incident occurred was a two story building in which multiple family members lived (father and mother lived on first floor and other family members with their siblings were living on the second floor (Figure-1), the deceased was found lying in the middle of his room (room consisted of a king size bed, a closet, an office desk and a chair) and close to him was a knife. Its full length was 21cm with a single metal blade 11cm long and a red plastic handle 10 cm long. Suspect blood-stains were found on the blade and handle (Figure-2A). The room was found untidy mostly due to personal carelessness and the room door showed signs of forced entry, other doors and windows in the room were locked from inside and no signs of forced entry was seen (Figure-2B). The carpet under the body was soaked with blood and no blood spatter was found in any area of the room. Furthermore, the blood-stains seen on the furniture in close proximity to the body were from hands (most probably those of the deceased). Crime scene investigators observed the difficulty for any stranger to enter the house and reach the deceased’s room without being noticed due to the number of people living in the house and the design of the house. No suicidal notes or personal diaries related to the deceased were found upon searching the room. Two medication packs prescribed by the psychiatric hospital to the deceased were found at the site. Ev-

idence was collected from the crime scene: medication packs, a red sharp knife 21 cm long, and blood spots from different areas in the victim's room (the room toilet door, chair, wall, room door, and deceased mobile phone), all the evidence collected was sealed and sent to the forensic laboratories for further investigation.

2.2. Autopsy Findings

Examination of the body revealed the following:

Upon examination, the deceased was wearing black shorts and boxers, without tear in the material.

A cut-throat injury almost completely encircled the neck (a small area in the posterior left side of the neck was spared from the injury of length:5cm). The wound although it was a clear gaping incised wound, its course around the neck was irregular suggesting that it was multiple deep cut wounds connected to each other to form a single large cut wound encircling the neck, the wound lied just below the posterior hair line directly passing under both angles of the lower jaw (about 3cm below) and 6 cm under the chin. Multiple superficial wounds were found in close proximity and parallel to the large incised wound in the front and back of the neck suggesting that they are hesitation marks (Figure-3). The incised wound was deep and included skin, superficial fascia, neck muscles and also upper anterior part of the larynx while sparing the common carotid and internal jugular arteries (Figure-4).

A stab wound 2.5 cm long was found directly medial to the left nipple and it passed through the fourth left intercostal space to the mediastinum without causing any injury to the heart or lungs or vessels in the area (Figure-5).

Two superficial cut wounds 1 cm long were found on the posterior aspect of the left index and middle finger. Examination also revealed that the internal organs in the body were pale which indicates that the deceased had bled to death.

The deceased's nails were collected and sent to the forensic laboratory for further investigations. Postmortem blood and urine samples were collected and sent to the toxicological laboratory for analysis.

2.3. Toxicological Analysis

Postmortem blood and urine samples were first examined using screening tests then samples are prepared using solid phase extraction and then examined using gas

chromatography tandem mass spectrometry (GC-MS-MS) for conforming the results, samples were examined for qualitative detection of antidepressants, alcohols, opioids, sedatives, hallucinogens, amphetamines. Lab results revealed the presence of Mirtazapine (anti-depressant drug) and Diazepam (anti-anxiety drug).

Two medication packs prescribed by the local psychiatric hospital to the deceased were found at the scene and collected by the crime scene team and sent to the lab. After examination, the collected packs were found containing two types of pills, the first was Diazepam (8 pills) and second was Mirtazapine (5 pills).

2.4. DNA Analysis

Samples examined were as follows:

- Blood spots from different areas in the victim's room.
- Victim's nail cuttings.
- Blood spots collected from victim's mobile phone.
- A red sharp knife, 21 cm long.

Samples were photographed, measured, traces were collected from knife, 2 swabs from the blade containing blood and epithelial cells and 2 swabs from the handle containing blood and epithelial cells. All samples were extracted using Chelex 5%. Polymerase chain reaction (PCR) completed on the samples using "Identifiler Plus Kit" which contains Primer and Master Mix including positive and negative controls, then genetically analyzed by Short Tandem Repeats (STR) 3130 XL using "Identifiler Plus Kit" which contains ladder and LIZ size standard. Results were obtained and analyzed using GeneMapper ID V3.2. All collected samples revealed no DNA other than the victim's DNA.

3. Discussion

This article sheds light on a case of fatal cut-throat death, discussion will handle the analysis of all the forensic evidences provided, which eventually demonstrate a clear conclusion about the manner of death as a suicidal cut-throat case.

When it comes to injuries, a neck injury has great importance, in respect to its situation and circumstances. The distinction between homicidal and suicidal neck injuries is essential; accidental cut-throat injuries are meanwhile rare [5].

The victim in this case, as shown from the history tak-



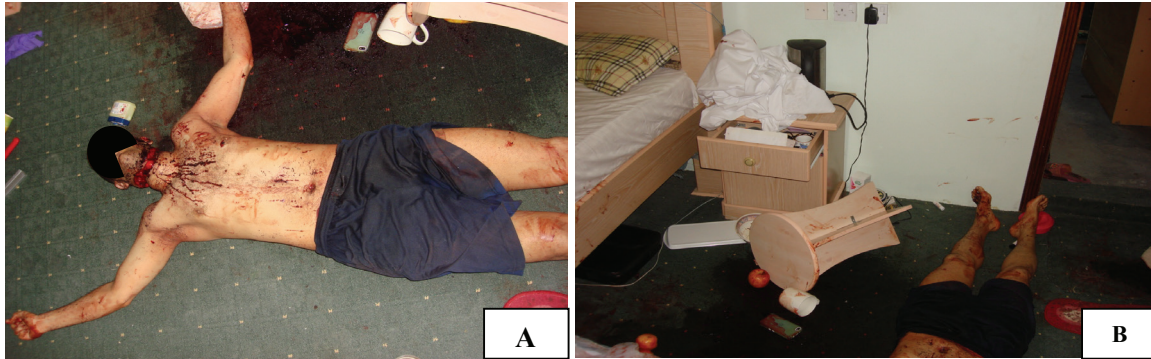

Figure 1- (A) and (B) Showing the position of the dead body at the death scene.




Figure 2- Death scene photos; (A) shows the forced entry signs on the room door; and (B) shows the knife used for suicide.

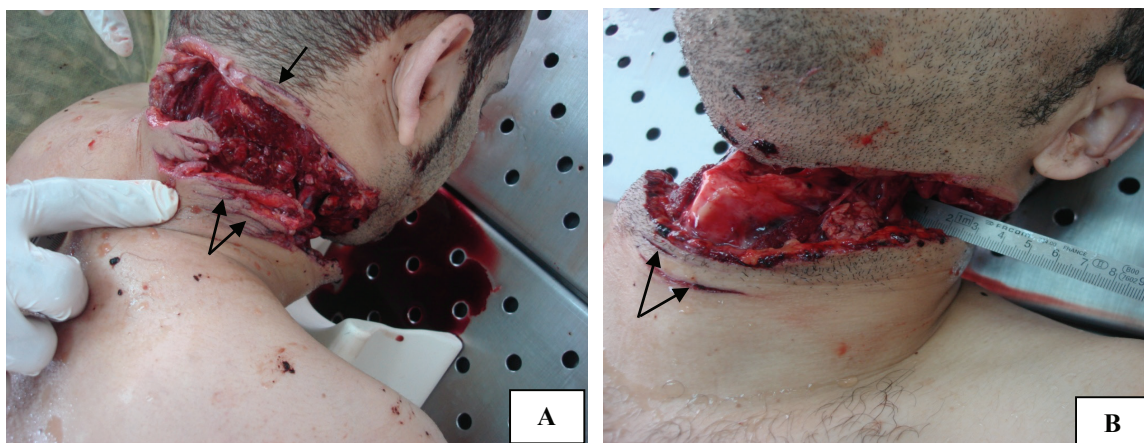


Figure 3- (A) and (B) demonstrate the pattern and course of the incised wound in the neck showing the hesitation marks (arrows).

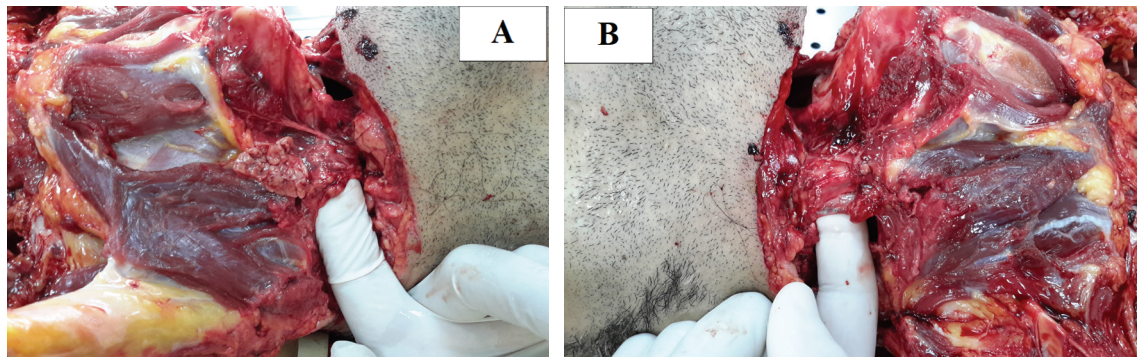

Figure 4- (A) and (B) show the spared carotid sheath within the cut-throat injury on both sides of the neck.

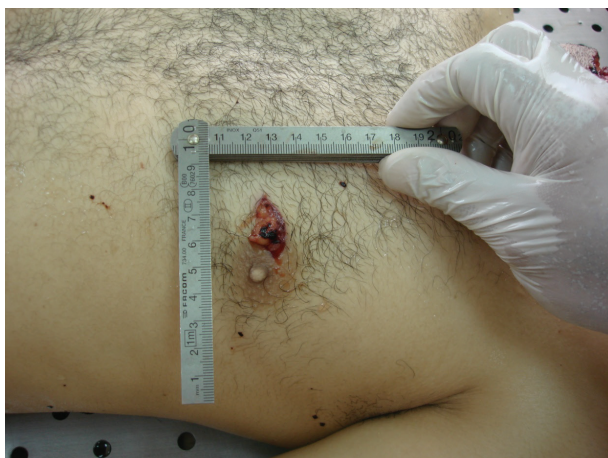

Figure 5- Stab wound found in the chest.

en, was an unemployed male suffering from a psychiatric illness (severe depression) and was under medication and even though he lived with his family, he was considered a loner and isolated as he was not married and lived in a separate room. According to the American Foundation for Suicide Prevention, suicide most often occurs when stress and health issues dominates to create an element of hopelessness and despair. Depression is the most common condition associated with suicide. Other risk factors and warning signs that also can affect are relationship problems, isolation, and unemployment [8]. A similar case was reported when a 27-years-old male attempted to commit suicide by cutting his throat after prolonged mental depression as a consequence of long term unemployment and poverty [9]. A study completed in India on cut-throat suicidal victims reported that the majority of cases were young adults, 82.35% in the age group of 20-40 years, 47.05% were suffering from acute and tran-

sient psychosis [10]. In Nigeria, a study reported that the relationship between unemployment and mental illness is bidirectional because individuals with mental illness are less likely to be employed than those without mental illness [11]. These preliminary findings in this report are in accordance with the previously mentioned studies and can all be considered as the first step in concluding the manner of death as suicide because these factors are usually associated with this manner of death.

The death scene initial findings were suggesting the suicidal scenario as the room was locked from inside, not easily accessible by strangers, and the victim's clothes were intact without tearing indicating a struggle.

The classical feature of a suicidal cut-throat incision is its obliquity, starting high on one side of the neck below the angle of jaw, ending at a lower level on the other side with the presence of tentative cuts [5]. The pattern found in this case although showing differences from the classic suicidal cut throat as it is multiple cuts connected together to form one major deep incised wound with the presence of hesitation cuts, it also presents itself as another evidence for suicidal manner of death as it is compatible with a person inducing the injuries to himself rather than being murdered by another person. Meanwhile, other reported cases showed that hesitation marks were not found in suicidal cut-throat deaths [12, 6]. It is well established that hesitation marks on the neck indicate repeated attempts to cut the neck that were ended due to pain and hesitating before finally cutting the skin [13]. As explained by literature the suicidal cut-throat wounds are located at higher level above thyroid cartilage, while the homicidal cuts are lower [7, 14]. In this case, the course of the cut wound was seen passing along the upper part of the neck and through the upper part of the larynx, which

support the studies demonstrated. It also worth mentioning that deep neck wounds are uncommon in suicidal deaths, however similar studies have also reported deep neck wounds extending to the vertebrae in suicidal deaths which can be attributed to psychiatric disorders [12].

In many studies the presence of self-inflicted wounds in other accessible areas of the body is not uncommon [15]. In this case, although there is a deep stab wound in the left side of the chest that can easily be attributed to a homicidal injury, in this particular situation due to deceased having a history of a major psychic disorder along with the aggressive pattern of the neck injury, it is logical to consider this a self-inflicted stab wound confirming the obvious insistence to commit suicide.

The DNA analysis of the evidences collected from the crime scene were negative for another perpetrator, therefore no clear evidence for the presence of a suspected assailant was found. Toxicological analysis of evidence shows the presence of anti-depressants and anti-anxiety medications, which were prescribed by the psychiatric hospital, thus confirming the presence of a psychiatric illness and depressive behavior that the deceased was suffering from and led him to commit suicide.

4. Conclusion

Throat-cutting is not a common method for suicide. Homicidal cut-throat injuries are more commonly reported. The most important task for forensic experts is to distinguish between suicidal and homicidal cut-throat injuries. Usually a cut-throat injury leading to death is suspected to be homicidal as it is difficult to accept and understand that somebody could slit his own throat to commit suicide. For this case the differentiation between varying manners of death required a complete and meticulous look at the history of the deceased, death scene investigation associated with a good autopsy all assisted in correctly establishing the specific manner of death and concluding that it was a suicidal case.

Medical and psychological assistance should be provided once the person presents with a suicidal tendency. Attempts should be made to reach out to these people and proper counselling should be made available to enable them to cope with life threatening or suicidal tendencies.

Acknowledgement

We would like to thank the Attorney General, Dr. Ali

Albuaineen for his constant support and encouragement, consultant Qutami AlQutami for the valuable guidance and forensic expert Ahlam Almajed for conducting the toxicological analysis. Our thanks extend to the forensic consultant Dr. Mona Awny for her scientific assistance.

Conflicts of interest

There are no conflicts of interest

References

1. Saeed A, Bashir MZ, Khan D, Iqbal J, Raja KS, Rehman A. Epidemiology of suicide in Faisalabad. *Journal of Ayub Medical College Abbottabad*. 2002;14(4).
2. Methods of suicide: international suicide patterns derived from the WHO mortality database (cited in May 8th 2020). Accessed from <https://www.who.int/bulletin/volumes/86/9/07-043489/en/>.
3. Al-Waheeb S, Al-Kandary N. Patterns of Suicide in Kuwait: a retrospective descriptive study from 2003–2009. *BMC public health*. 2015 Dec 1;15(1):527. <https://doi.org/10.1186/s12889-015-1862-7>
4. Demirci, S., Dogan, K. H., & Gunaydin, G. (2008). Throat-Cutting of Accidental Origin. *Journal of forensic sciences*, 53(4), 965-967. <https://doi.org/10.1111/j.1556-4029.2008.00764.x>
5. Kumar S A, Kumar Ms V, Babu YR, Prasad M. A case of “atypical homicidal” cut-throat injury. *Medico-Legal Journal*. 2016 Sep;84(3):156-8. <https://doi.org/10.1177/0025817216656582>
6. Waghmare PB, Bhise SS, Nanandkar SD. Cut Throat Injury: Homicidal or Suicidal? Crime Scene Visit Solved the Mystery.
7. Ohshima T, Kondo T. Eight cases of suicide by self-cutting or-stabbing: consideration from medico-legal viewpoints of differentiation between suicide and homicide. *Journal of clinical forensic medicine*. 1997 Sep 1;4(3):127-32. [https://doi.org/10.1016/s1353-1131\(97\)90092-4](https://doi.org/10.1016/s1353-1131(97)90092-4)
8. Risk factors and warning signs [Internet]. American Foundation for Suicide Prevention. 2019 [cited 2020 May 6]. Available from: <https://afsp.org/risk-factors-and-warning-signs>. <https://doi.org/10.1037/e587752012-001>
9. Biswas S, Bandyopadhyay C, Biswas S, Dalal D, Roy S. Multiple Violent Suicidal Attempts by One Men-

- tally Ill Person: A Rare Case. *Journal of Indian Academy of Forensic Medicine*. 2015;37(3):325-7. <https://doi.org/10.5958/0974-0848.2015.00085.8>
10. Krishnatreya, Manigreeva, et al. "A Study on Behavior and Management of Suicidal Cut Throat Patients." *Journal of Laryngology and Voice*, vol. 3, no. 2, 2013, p. 57. doi:10.4103/2230-9748.132051. <https://doi.org/10.4103/2230-9748.132051>
11. Adoga AA, Ma'an ND, Embu HY, Obindo TJ. Management of suicidal cut throat injuries in a developing nation: three case reports. *Cases journal*. 2010 Dec;3(1):65. <https://doi.org/10.1186/1757-1626-3-65>
12. Patil SS, Deokar RB, Vidhate SG, Tyagi S. An atypical case of suicidal cut throat injury. *Egyptian Journal of Forensic Sciences*. 2016 Dec 1;6(4):492-5. <https://doi.org/10.1016/j.ejfs.2016.04.003>
13. Racette S, Kremer C, Desjarlais A, Sauvageau A. Suicidal and homicidal sharp force injury: a 5-year retrospective comparative study of hesitation marks and defense wounds. *Forensic science, medicine, and pathology*. 2008 Dec 1;4(4):221-7. <https://doi.org/10.1007/s12024-008-9046-8>
14. Knight B and Saukko P. *Knight's Forensic Pathology* 3rd ed. London: Arnold: (2004) 235-239.
15. Yadav A, Raheel MS, Kumar R L, Sharma SK, Kanwar H. Cut-throat wounds: Suicidal and homicidal—two case reports and review of literature. *Medicine, Science and the Law*. 2016 Jan;56(1):53-7. <https://doi.org/10.1177/0025802415591200>

