



Naif Arab University for Security Sciences  
Arab Journal of Forensic Sciences & Forensic Medicine  
المجلة العربية لعلوم الأدلة الجنائية والطب الشرعي  
<https://journals.nauss.edu.sa/index.php/AJFSFM>



## Hepatorenal Effects of Diclofenac and Ciprofloxacin in Rats

التأثيرات الناتجة عن استخدام عقاري الديكلوفيناك والسيبروفلوكساسين على الكبد والكلى لدى الجرذان



CrossMark

Elkhatim H. Abdelgadir<sup>1</sup>, Khalid O. Alzaidi<sup>1</sup>, Mohamed E. Ramady<sup>2</sup>, Sayed A. M. Amer<sup>1,3,\*</sup>

<sup>1</sup>Department of Forensic Sciences, College of Criminal Justice, Naif Arab University for Security Sciences, Riyadh, Saudi Arabia.

<sup>2</sup>The Department of Forensic Medicine, Ministry of Justice, Alexandria, Egypt.

<sup>3</sup>Faculty of Science, Cairo University, Giza, Egypt.

Received 02 May 2021; Accepted 12 Aug. 2021; Available Online 30 Dec. 2021

### Abstract

The toxic effect of diclofenac (DCF) sodium and Ciprofloxacin (CIP) on gene expression of cytochrome P450 oxidase (CYPs) and the histology of liver and kidney of male albino rat has been evaluated in this study. DCF and CIP were chosen since they are inhibitors for specific CYP enzymes.

Thirty-five adult male albino rats were divided into 7 groups of 5 animals each (A, B, C, D, E, F and G) and were treated orally with drugs for 21 consecutive days. Group A served as the control while B and C were treated with 5.3, 10.6 mg/kg body weight (bw) DCF sodium and groups D and E were treated with 40 and 80 mg/kg bw CIP, respectively. Groups F and G were treated with a mixture of the low and the high doses of both drugs, respectively.

Both drugs significantly downregulated the mRNA expression of CYP1a2, CYP3a4 and CYP2c9. They caused hepatorenal histological changes. In the liver, massive fibrosis, necrosis, inflammatory cell infiltration with hemorrhages and hydrophilic degeneration have

### المستخلص

جرى في هذه الدراسة تقييم التأثيرات السمية لديكلوفيناك الصوديوم (DCF) والسيبروفلوكساسين (CIP) على التعبير الجيني للسيتوكروم بي 450 أكسيداز (CYPs) وعلى أنسجة الكبد والكلى لدى ذكور الجرذان البيضاء. واختير عقارا ديكلوفيناك الصوديوم (DCF) والسيبروفلوكساسين (CIP) نظرًا لأنهما مثبطان لأنزيمات معينة من سيتوكروم بي 450 أكسيداز (CYPs-P450). وتم تقسيم حيوانات التجربة (35) من ذكور الجرذان البيضاء البالغة) إلى 7 مجموعات (A, B, C, D, E, F, G) تتألف كل منها من 5 أفراد، وتم إعطاؤها العقارين عن طريق الفم لمدة 21 يومًا متتاليًا. المجموعة (A) هي المجموعة الضابطة، بينما تم إعطاء الجرذان في المجموعتين (B) و (C) جرعة ديكلوفيناك الصوديوم (DCF) بمقدار 5.3 و 10.6 ملغم/كغم من وزن الجسم على التوالي. في حين تم إعطاء أفراد المجموعتين (D) و (E) جرعة سيبروفلوكساسين (CIP) بمقدار 40 و 80 ملغم/كغم من وزن الجسم على التوالي. وتم إعطاء أفراد المجموعتين (F) و (G) مزيجًا من الجرعات القليلة والجرعات الكبيرة من كلا العقارين على التوالي. خُفِّصَ كل من العقارين إلى حد كبير من تعبير الحمض النووي الريبي المرسل (mRNA) لكل من السيتوكروم CYP1A2 والسيتوكروم CYP3A4 والسيتوكروم CYP2C9. كما تسبب العقاران بحدوث تغييرات نسيجية في الكبد والكلى. في الكبد تمت ملاحظة وجود

**Keywords:** Forensic Science, Toxicity, CYP450, Histopathology, Anti-inflammatory Drugs.

**الكلمات المفتاحية:** علوم الأدلة الجنائية، السمية، السيتوكروم بي 450 أكسيداز، علم أمراض الأنسجة، العقاقير المضادة للالتهابات.



Production and hosting by NAUSS



\* Corresponding Author: Sayed A. M. Amer

Email: [samer@nauss.edu.sa](mailto:samer@nauss.edu.sa)

doi: [10.26735/PTLD3586](https://doi.org/10.26735/PTLD3586)

been observed. A massive tissue injury with glomerular and tubular damages due to sever necrosis, degeneration of concomitant inflammatory cells and blood vessels congestion have been shown in renal tissues.

Although DCF and CIP are still used as therapeutic drugs, their use should be limited as their chronic administration induces a toxic effect on human health.

## 1. Introduction

Diclofenac (DCF) has a distinct chemical composition and shows a significant anti-inflammatory effect on animals and humans [1]. It shows pharmacologic activities, antipyretic and analgesic properties [2]. DCF sodium acquires a broad therapeutic scope. Its gastrointestinal endurance is also better than other highly active anti-inflammatory non-steroid drugs. Biologically active metabolites are presented in humans during the biotransformation of DCF sodium. The activity of DCF metabolites is considerably weaker than unchanged DCF sodium [2] and comparable to or more powerful than phenylbutazone [3].

Ciprofloxacin (CIP) is a fluoroquinolone which acts as an antimalarial drug [4]. CIP, a well used second-generation quinolone characterized by being a suppressor of bacterial DNA gyrase, was shown to inhibit topoisomerase II in the mammalian cells. It also induces cell cycle suppression, creates DNA double-strand breaks and initiates in-vitro apoptosis in cancer cells. Based on these actions, its anticancer effects were evaluated in human and murine cancer cell lines [5]. It is practiced managing bacterial infections of gastrointestinal tract, intra-abdominal, lung, skin, bone and joints [6].

Metabolism of different endogenous and exogenous substrates is catalyzed mainly in liver tissues by cytochrome P450 enzymes (CYPs) [7]. These cytochromes represent the common enzyme families for metabolizing different toxic chemicals and drugs including therapeutic ones [8]. They also catalyze

تليف كبير، ونخر، وتسلسل الخلايا الالتهابية، ونزيف، وتنكس مائي. وفي الكلى تمت ملاحظة وجود إصابة بالغة في الأنسجة، بالإضافة إلى تلف أنبوبي وكبيبي بسبب النخر الشديد، وتنكس الخلايا الالتهابية المرافقة، وكذلك وجود احتقان للأوعية الدموية. وعلى الرغم من استمرار استخدام ديكلوفيناك الصوديوم (DCF) والسيبروفلوكساسين (CIP) كعقاقير علاجية، فإن استخدامهما يجب أن يكون محدوداً؛ لأن إعطاؤهما بشكل مزمّن له تأثير سُمي على صحة البشر.

most lipophilic xenobiotic oxidative biotransformation and are thus of high value for clinical pharmacology [9]. Enhancing or inhibiting CYP3a4 expression is a primary clinical key for drug-drug interactions in patients administered with repetitive CYP3a4-metabolising drug doses. CYP 1a2, CYP3a4 and CYP2c9 are among the enzymes included in DCF and CIP metabolism [10-14]. More than half of clinically used drugs are catalyzed by CYP3a4 [15]. Co-administration of CIP abolished the enterohepatic circulation of DCF, leading to reduction in the plasma content of DCF [16].

Despite its therapeutic benefits, DCF induced hepatorenal toxicity in rats by triggering histological injury in both organs [17-20]. CIP also induces histopathological alterations in the hepatorenal tissues like necrosis, vacuolar degeneration, inflammatory cells infiltrations, and congestion in blood vessels [21]. Administration of CIP during pregnancy caused oxidative damage in fetal liver tissue. The drug caused central vein dilation, portal vein congestion, pyknotic nuclei and cytoplasmic vacuolization in fetal rat liver [22].

Therapeutic administration of DCF and/or CIP could induce different pathological alterations on molecular and histological levels indicating their toxic effects. The present study, therefore, aimed to explore the toxic effect of both drugs on some molecular and histological parameters of male albino rat after therapeutic administration of both drugs for 21 consecutive days.



## 2. Materials and Methods

### 2.1 Animals

Thirty-five male Wistar rats 12-week-old (220-260g) were obtained from the Animal Care Center, College of Pharmacy, King Saud University, Riyadh, Saudi Arabia. Animals were maintained on a 12 h light/dark in cycle polypropylene cages (six rats in each) at ambient temperature of  $22 \pm 1$  °C and relative humidity of 50-60% with food and water provided ad libitum. All experiments were carried out according to the recommendation of Experimental Animals Ethics Committee in Naif Arab University for Security Sciences which operates in accordance with the international standards for handling of experimental animals. The rats were acclimatized for 1 week before the experiment.

### 2.2 Chemicals

Kits used for gene expression of CYP450 were from QIAGEN Inc, USA. DCF sodium was 50 mg tablet's form and CIP were 500 mg tablets from Hikma Pharmaceuticals (Jordan). Tablets were dissolved in double distilled water before use. Sub-acute toxicity study (21-day repeated oral administration) was carried out according to OECD 407 guidelines [23].

### 2.3 Drug dosage

We chose the concentration according to (1/10 LD50) for the low dose and (1/5 LD50) for the high dose. For DCF, the maximum human therapeutic dose (150 mg/kg) was adjusted to suit the rat's weight [24] so, the dose used in this study was below the maximum daily dose (5.3 – 10.6 mg/kg). CIP dosage was based on the therapeutic dose given to Wistar rats twice daily [25]. The equivalent concentration of drug dose was dissolved in 1 ml double distilled water and given orally once a day. The

rats were administered the doses by oral gavage up to 21 consecutive days as this period is usually elapsed for treatment.

### 2.4 Experimental design

Rats were randomly divided into seven experimental groups of 5 rats each and were orally treated for 21 consecutive days. Rats in group A served as control and received distilled water. Rats in groups B and C were given DCF sodium (5.3, mg/kg bw and 10.6 mg/kg bw, respectively). Rats in groups D and E were given CIP (40mg/kg bw and 80mg/kg bw, respectively). Group F was given DCFS 5.3, mg/kg bw and CIP 40mg/kg bw. Group G was given DCF sodium 10.6 mg/kg bw and CIP 80mg/kg bw. Rats were observed twice daily for recording any clinical signs, the time of onset, duration of symptoms, mortality and morbidity. Body weight was recorded once before the start of dosing, once weekly during the treatment period and finally on the day of sacrifice.

### 2.5 CYP450 gene expression

100 mg of the liver tissue was homogenized in 1 mL QIAzol (QIAGEN Inc., Valencia, CA). 0.3 mL chloroform was added to the homogenate. The mixture was shaken and centrifuged for 30s at 4°C (12,500 rpm) for 20 minutes. The supernatant was isolated in a new tube and an equal volume of isopropanol was added, then vortexed for 15s and centrifuged at 4°C and 12,500 rpm for 15 minutes. Pellets were washed by 70% ethanol and dried at room temperature. The pellets were dissolved using nuclease-free water. The concentration of the extracted RNA was measured by a Nanodrop device (NanoDrop™ 8000 Spectrophotometer, Thermo Scientific™, USA) at wavelength 260 and 280nm.

Following the protocol provided by Promega Inc. (Reverse Transcription System, Promega Corpora-



**Table 1-** Primers used for gene expression.

Name	Sense 5'....3'	Sense 3'....5'	AnnealingTemp (°C)	bp
β-actin	GAGCACAGAGCCTCGCCTTT	AGAGGCGTACAGGGATAGCA	62	360
CYP1A2	GCAGGTCAACCATGATGAGAA	CGGCCGATGTCTCGGCCATCT	56	334
CYP2C9	CTTGACACCACTCCAGTTGTC	AGATGGATAATGCCCCAGAG	58	133
CYP3A4	CCCCTGAAATTAAGCTTAGGAG	TAATTTGAGGTCTCTGGTGTCTCA	54	162

tion, USA) cDNA synthesis was carried out in PeX system 0.5 Thermal Cycler (Thermo Electronic Corporation, Upland, CA 91786, USA) as described by Ibrahim et al. [26]. The obtained cDNA was kept at -20°C to perform the reverse transcription-polymerase. 25-μL reaction mixture tube contained 0.075 μl of 10 μM forward and reverse primers (Table-1), 12.5 μL of SYBR green universal Mastermix, 11.15 μL of nuclease-free water and 1.2 μL of cDNA sample was prepared. The fold change in the expression of the targeted CYP isoforms between drug-treated and control rats was corrected by the levels of a reference control. Assay controls was incorporated onto the same plate, namely, no-template controls to test the contamination of any assay reagents. The RT-PCR data was analyzed using the relative gene expression (i.e., ΔΔ CT) method [27]. Briefly, the data are presented as the fold change in gene expression normalized to the endogenous reference gene β-actin and relative to a calibrator. The fold change in the level of target genes between treated and untreated cells, corrected by the level of β-actin was determined using the following equation: fold change =  $2^{-(\text{untreated})\text{Ct} - (\text{treated})\text{Ct}} / 2^{-(\beta\text{-actin})\text{Ct}}$ .

## 2.6 Histology

After 3 weeks of treatment, 3 rats from each group were killed under diethyl ether anesthesia to identify gross lesions. Liver and kidney were weighed and preserved in 10% neutral buffered for-

malin and trimmed. A 5μ thickness of tissue sections were stained with hematoxylin and eosin for histopathological study.

## 2.7 Statistical analysis

The mRNA expression was calculated for the control and drug treated rats by using the average relative Ct values (2-ΔΔCT method). Significance of the mRNA expression was statistically calculated by the two-tailed, two sample t-test with equal variance. *p*-value less than 0.05 were considered statistically significant [28].

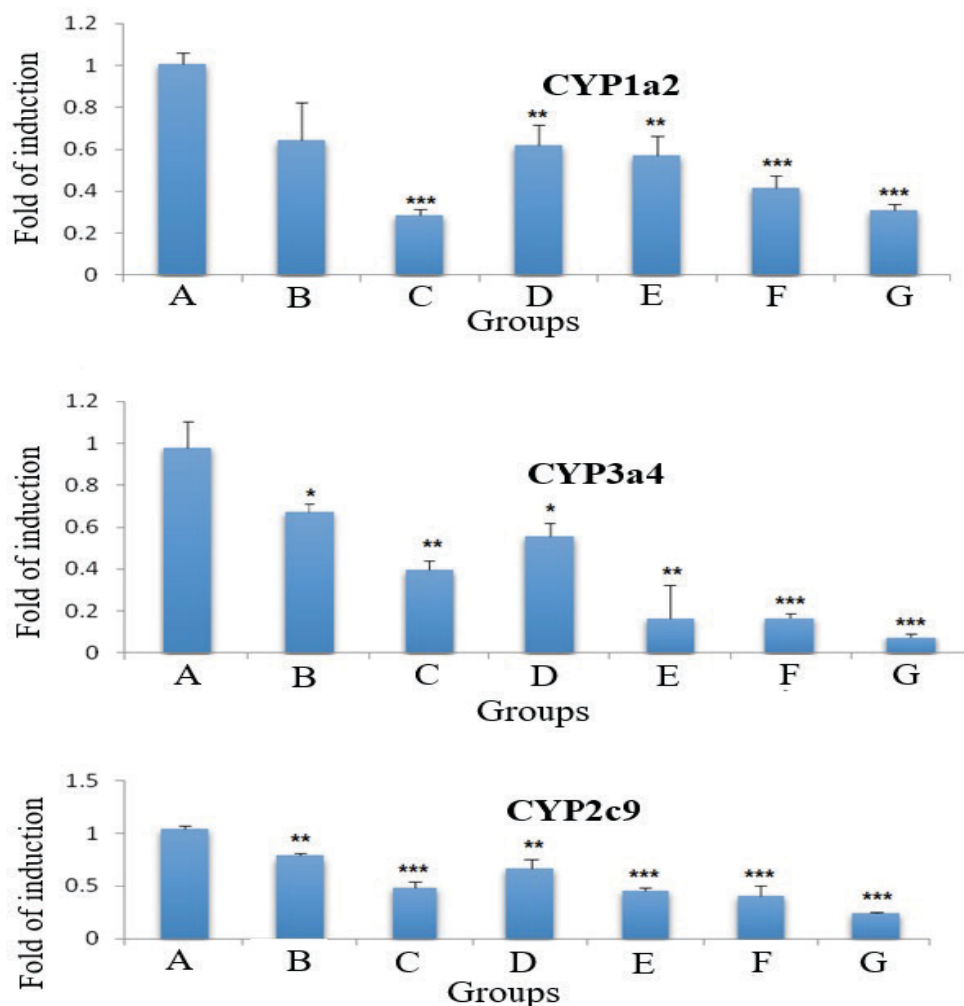
## 3. Results

### 3.1 Gene expression

The present study selected one representative isoform from three families of CYP450 enzymes (1a2, 2c9 and 3a4) and investigated their mRNA gene expression in detoxifying DCF and CIP effects since these isoforms play a dominant role in the metabolism of drugs and other xenobiotics.

The effect of DCF and/or CIP on rat liver mRNA expression of CYP1a2, CYP2c9 and CYP3a4, respectively are shown in Figure-1. Either DCF and/or CIP significantly downregulated the mRNA expression levels of CYP1a2 as compared to control rats (*p* < 0.01, *p* < 0.001). The low dose of DCF (group B) did not significantly affect the mRNA expression of CYP1a2 although the expression decreased with 0.64 times more than in the control group. The range of the gene downregulation was between 0.64 in rats





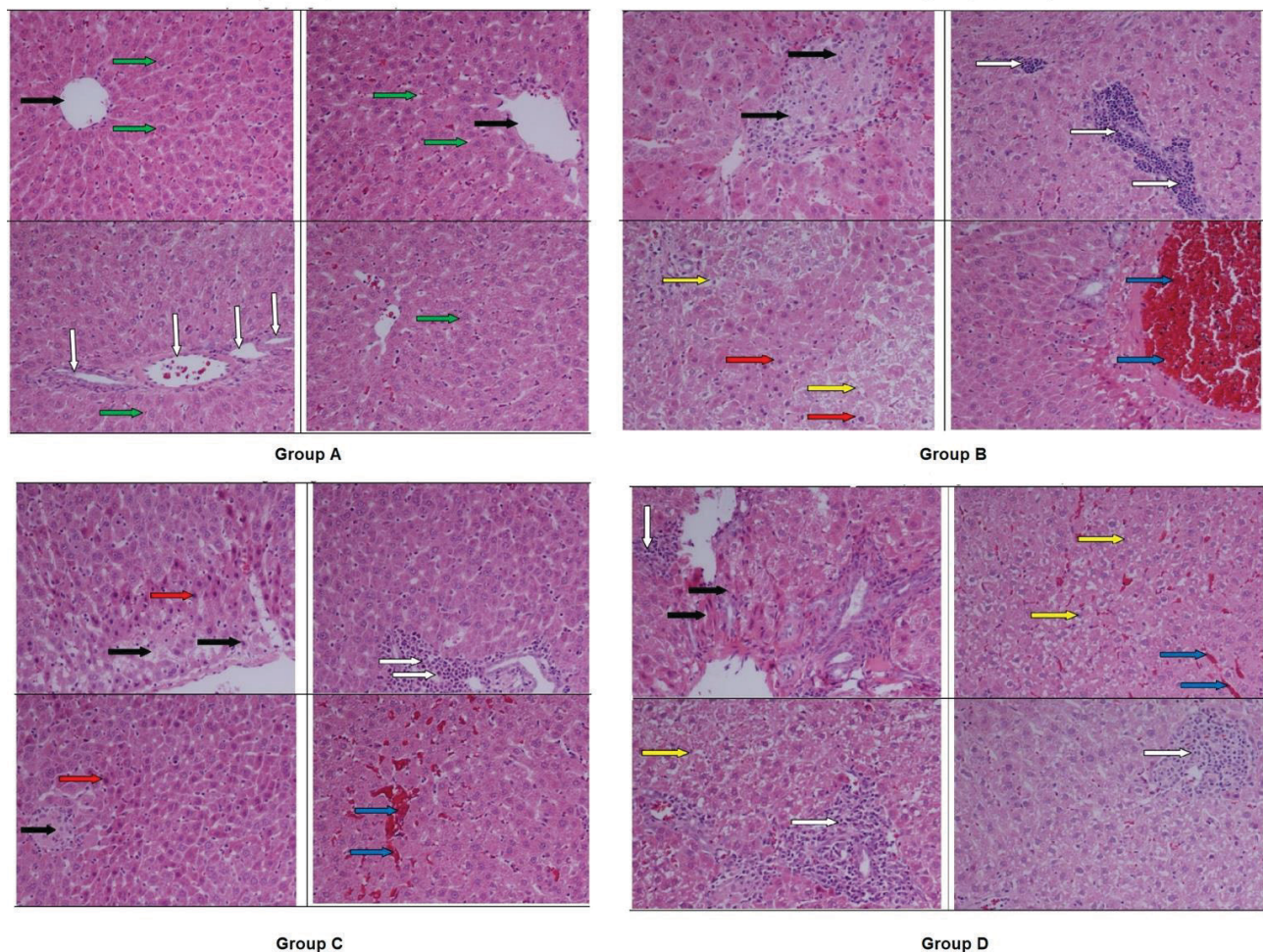
**Figure 1-** The effect of DCF sodium and/or CIP on rat liver CYP mRNA expressions. Results are mean  $\pm$  SE (n= 5). (\*p < 0.05, \*\*p < 0.01, \*\*\*p < 0.001 treated compared to the control).

treated with low dose of DCF to 0.29-fold in rats treated with high dose of the same drug ( $p < 0.001$ ). Similarly, the expression of CYP3a4 mRNA levels was also significantly downregulated in rats treated with each of the two drugs or both (combined) by 0.71 and 0.15 times. The most downregulated gene was shown in Group G rats treated with the high dose of both drugs ( $p < 0.001$ ). Meanwhile, the expression of CYP2c9 exhibited a gradual significant decrease from 0.75 times in rats treated with low dose DCF (Group B) to 0.22 times in rats treated with high dose (group G) of both drugs ( $p < 0.001$ ).

### 3.2 Histopathology

There were no microscopic changes in liver tissues of the control rats (Figure-2A). Acute histopathological changes include liver necrosis, few lymphocytes infiltration, dilated sinusoids and central artery congestion were observed in the liver tissues. 5.3 mg/kg bw DCF sodium (group B) showed focal necrosis, focal inflammatory cell diffusion, degeneration with nuclear pyknosis and vessels congestion (Figure-2B). DCF sodium of 10.6 mg/kg bw (group C) showed central zonal necrosis, cell infiltration around portal triads, focal necrosis, pyk-





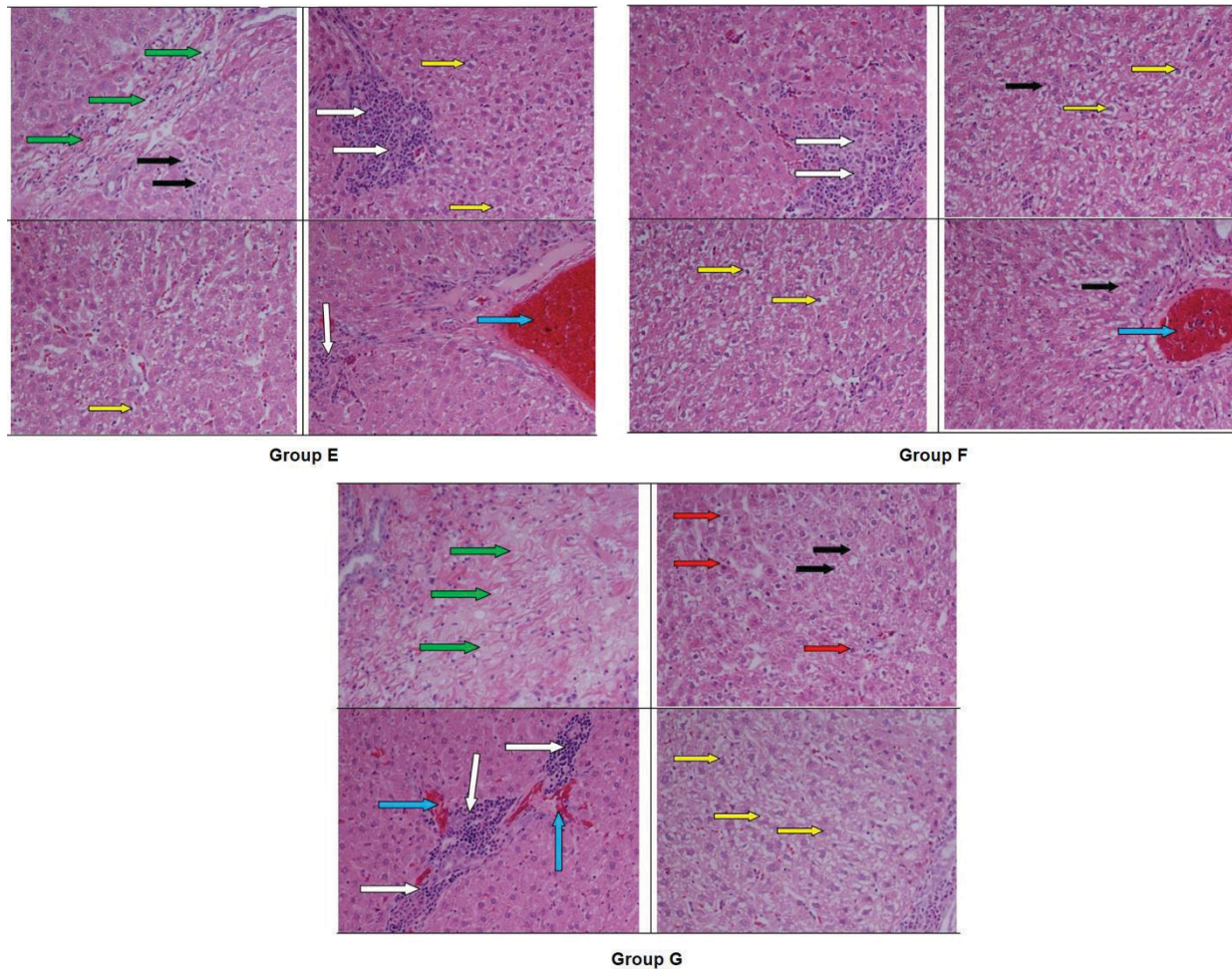
**Figure 2-** Normal hepatic tissues (group A) show cords of hepatocytes (green arrows), central veins (black arrows) and portal triad area (white arrows). Injured hepatic tissues (group B) in the form of necrosis (black arrows), focal inflammatory cell diffusion (white arrows), degeneration (yellow arrows) with pyknosis (red arrows) and vessels congestion (blue arrows). Liver tissues of rats of group C show central zonal and necrosis (black arrows), cell infiltration (red arrows), and hemorrhages (blue arrows). Liver sections of group D show severe inflammatory cells infiltration (white arrows) with an eroded portal triad, central zonal bridging necrosis (black arrows), severe parenchymatous degeneration (yellow arrows) and congested sinusoids (blue arrows).

nosis and hemorrhages (Figure-2C). 40 mg/kg bw CIP (group D) showed inflammatory lymphocytes infiltration with an eroded portal triad, central zonal bridging necrosis, severe degeneration and congested sinusoids (Figure-2D). 80 mg/kg bw CIP (group E) showed massive necrosis and onset of fibrosis develops inflammatory lymphocytes diffusion, degeneration and vessels congestion (Figure-3E). A mixture of 5.3 mg/kg bw DCF sodium and CIP of 40 mg/kg bw (group F) showed lymphocyte infiltration,

hydrophilic degeneration (cell swelling) and focal necrosis with disorganized hepatocyte cords and vessels congestion (Figure-3F). A mixture of 10.6 mg/kg bw DCF sodium and 80 mg/kg bw CIP (group G) showed massive fibrosis, necrosis, inflammatory cell infiltration with hemorrhages and hydrophilic degeneration (Figure-3G).

There were no microscopic changes in kidney tissues of the control rats (Figure-4A). DCF sodium of 5.3 mg/kg bw (group B) caused massive cellular



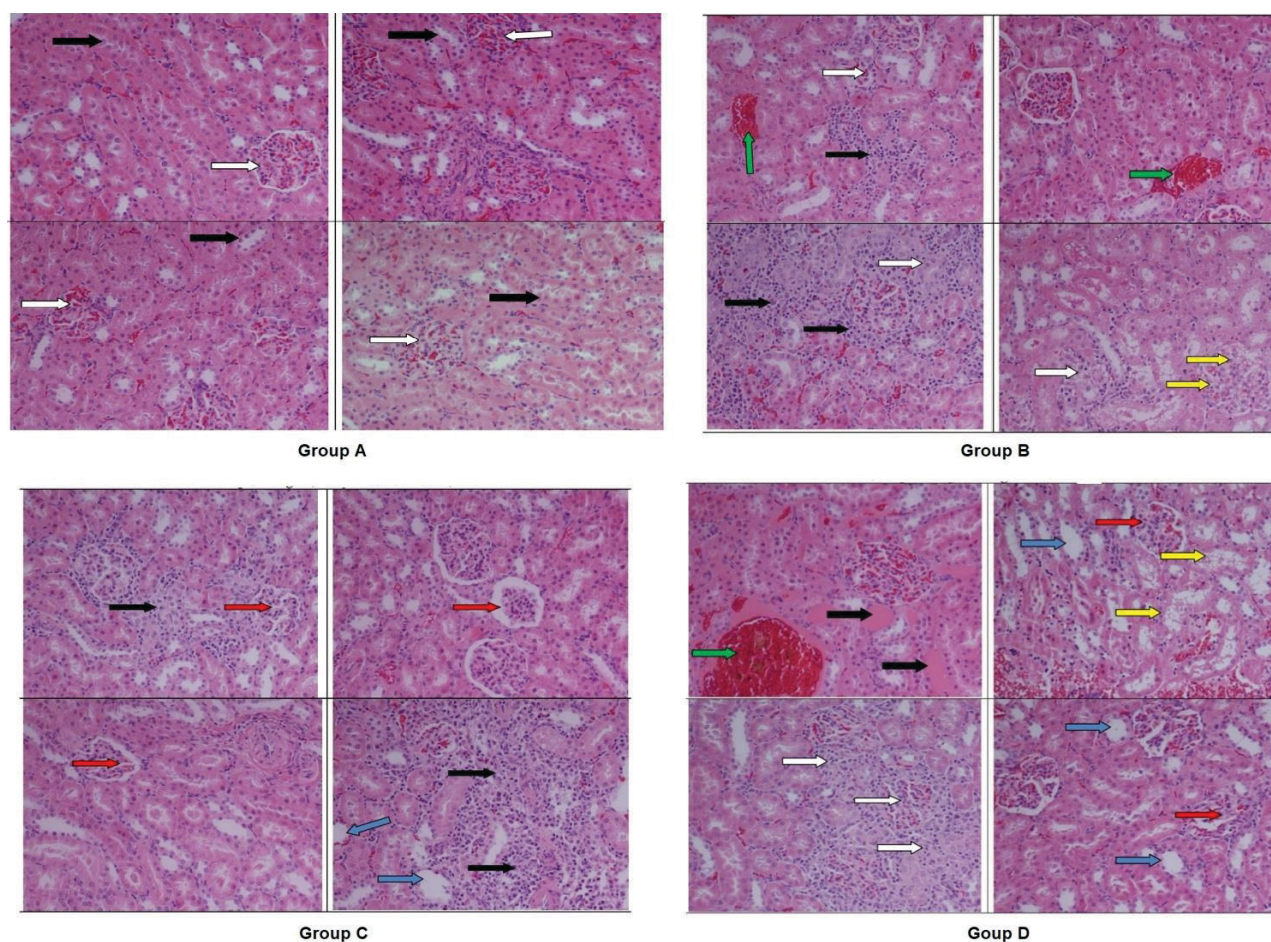


**Figure 3-** Liver sections of group E show massive necrosis (black arrows), onset of fibrosis (green arrows), inflammatory cell diffusion (white arrows), degeneration (yellow arrows) with and vessels congestion (blue arrows). Group F liver shows cell infiltration (white arrows), hydrophilic degeneration (cell swelling; yellow arrows) and focal necrosis (black arrows) with disorganized hepatocyte cords and vessels congestion (black arrows). Liver sections of group G show massive fibrosis (green arrows), necrosis (black arrows), pyknosis (red arrows), inflammatory cell infiltration (white arrows) with hemorrhage (blue arrows) and vacuolar degeneration (yellow arrows).

infiltration, tubular necrosis and dilation, glomerular cells degeneration and blood vessels congestion (Figure-4B). DCF sodium of 10.6 mg/kg bw (group C) revealed glomerular atrophy, intratubular inflammatory cell diffusion and tubular dilation (Figure-4C). CIP of 40 mg/kg bw (group D) showed severe damage of renal tissues and mesangial, podocytes and tubulointerstitial cells were affected. Glomerular and tubular hypertrophy in addition to tubular necrosis and dilation have been observed (Figure-4D). CIP

of 80 mg/kg bw (group E) showed severe tubular necrosis, inflammatory cell diffusion and disturbance in distal and proximal convoluted tubules and vessels congestion (Figure-5E). A mixture of 5.3 mg/kg bw DCF sodium and CIP of 40 mg/kg bw (group F) showed cell infiltration, tubular necrosis, glomerular atrophy with basement membrane distracted, tubular dilation, vacuolization due to degeneration (Figure-5F). A mixture of 10.6 mg/kg bw DCF sodium and 80 mg/kg bw CIP (group G) showed massive





**Figure 4-** kidney tissues of group A show normal glomeruli (white arrows), normal renal tubules (black arrows) with intact well organized cellular boundary. Kidney tissues of group B show massive glomerular and tubule-interstitial infiltration (black arrows) led to tubular necrosis (white arrows), glomerular cell degeneration (yellow arrows) and blood vessels congestion (green arrows). Severe renal injury in group C shows glomerular atrophy (red arrows), tubule-interstitial inflammatory cell diffusion (black arrows) and tubular dilation (blue arrows). Kidney tissues of group D show severe damage in mesangial cells, podocytes and tubule-interstitial cells (white arrows), glomerular hypertrophy (red arrows) and congestion (green arrow), tubular necrosis (black arrows) and dilation (blue arrows).

renal tissues injuries with glomerular and tubular damages due to sever necrosis, degeneration concomitant inflammatory cell and blood vessels congestion (Figure-5G).

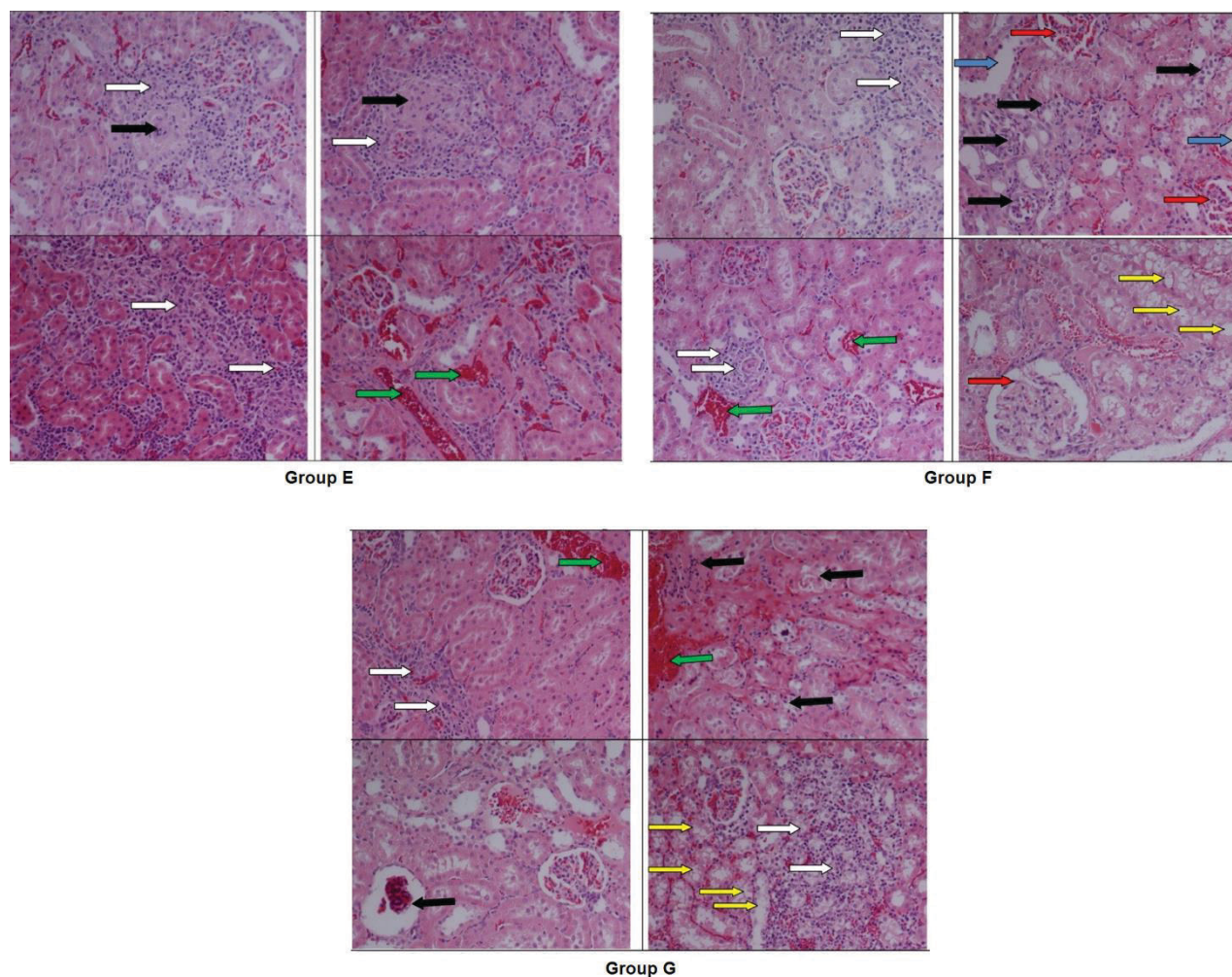
#### 4. Discussion

Among 57 putative functional CYPs, a dozen is categorized under CYP1, 2, and 3 families. Approximately, 80% of clinical drugs biotransformation happened by these three families. The present study selected one representative CYP enzyme from these

families which are: 1a2, 2c9 and 3a4. The mRNA gene expression of these enzymes has been investigated since they play a dominant role in the metabolism of drugs and other xenobiotics [8,15,29] as they obviously vary in their expression and activities through drug pharmacokinetics. Among the highest expressed forms in the liver are CYPs 3a4, 2c9, 2c8, 2e1 and 1a2 [30]. Their activities vary by the variability in their coding genes polymorphisms or in the regulatory mechanisms of drugs by either inhibition or induction [13]. Among these three isoforms,







**Figure 5-** Kidney tissues of group E show tubular necrosis (black arrows), inflammatory cell infiltration (white arrows), distal and proximal convoluted tubules disturbance and vessels congestion (green arrows). Kidney tissues of group F show tubule-interstitial cells infiltration (white arrows), tubular necrosis (black arrows), glomerular atrophy (red arrows), tubular dilation and vacuolar degeneration (yellow arrows). Massive renal tissues injury of group G show tubular and glomerular damage due to severe necrosis (black arrows), degeneration (yellow arrows), concomitant inflammatory cells (white arrows) and blood vessels congestion (green arrows).

CYP3a4 is the highest common isoform metabolizing the widest varieties of drugs and other xenobiotics [29,31]. Different combination mechanisms and factors could affect the CYP expression in liver. These factors include induction by hormones, xenobiotics, disease, polymorphisms, sex, cytokines, age and others. Inflammation induces downregulation in the mRNA expression of most CYP isoforms [28]. CYP 1a2, 2c9 and 3a4 metabolize different drugs among which are DCF and CIP [11]. CYP1a2

and CYP3a4 are inhibited by CIP while CYP2c9 is inhibited by DCF [13]. Ohyama et al. [10] found that DCF inhibited human cytochrome CYP1a2 and CYP3a4 mRNA expression.

CIP is one of the potent inhibitors of CYP1a2 [14], while the non-steroidal anti-inflammatory DCF is one of the main substrates and inhibitors of CYP2c9 [32]. The increase in the inhibition of the CYP mRNAs after the co-administration of both drugs could be explained by the increase in maximum



plasma concentration of CYP2c9. It could be also explained by a decrease in total body clearance of CIP with concurrent administration of DCF [16]. CIP attenuates enterohepatic circulation of DCF and moderates DCF-induced enteropathy, through the inhibition of intestinal  $\beta$ -glucuronidase activity [16]. Meanwhile, co-administration of DCF and CIP significantly inhibit CYP2c9. Amino acid polymorphism in the expressed CYP2c9 protein exhibits leucine amino acid at the position 359 which could diminish the metabolic capacity of DCF and CIP [33]. In agreement with Zhong et al. [16], the inhibitory effects of DCF, in the present study, was more on the expression of CYP2c9 than on the expression of the other two CYP isoforms. On the contrary, the expression of CYP1a2 and CYP3a4 mRNAs was more in the group "D" treated with CIP.

As reported by Adeyemi and Olayaki [18], hepatotoxicity by administration of 10 mg/kg body weight DCF was found in the form of a significant distortion of the hepatic tissue integrity. Similar dose of this drug given to adult male rats for 28 days induced an increase in the levels of inflammatory infiltration of the hepatorenal tissues [19]. Administration of 30 mg/kg bw DCF sodium for 30 days to male rats caused hepatorenal like injuries that recorded in the present study [20]. Similarly, hepatorenal histopathological abnormalities were shown by CIP toxication. Male Wistar rats administrated 100 mg/kg bw CIP for 30 days showed necrosis, vacuolar degeneration, inflammatory cells infiltrations and congestion in blood vessels of the hepatorenal tissues [21]. Liver tissues of the fatal rats treated with 20 mg/kg bw CIP exhibited central vein dilation, portal vein congestion, pyknotic nuclei and cytoplasmic vacuolization [22].

A significant decrease in clearance and significant increase in maximum serum concentration of

CIP have been reported when CIP is administrated in concurrent with DCF sodium. Co-administration of both drugs also causes an increase in peripheral tissue distribution of CIP as DCF increases the extent of absorption, serum concentration ( $C_{max}$ ) and the area under the curve (AUC) while decreases the total body clearance of CIP [34]. This may explain that co-administration of CIP could attenuate enterohepatic circulation of DCF and alleviated DCF-induced enteropathy. Sever hepatic injuries and nephrotoxicity have been reported to be induced by DCF and by CIP as well [35-38]. On the other hands, DCF causes dose-dependent significant increase in renal and hepatic fibroses [39] but CIP does not [40,41], however, the molecular mechanism is not yet fully explored. Based on the above-mentioned information and due to the significant inhibition of the primary DCF metabolic pathways (CYP2c9 and CYP3a4) particularly when used in combination with CIP, the alternate metabolic pathway (UGT 2B7) may be increased, resulting in formation of DCF-protein adducts that can induce hepatotoxic immune response [42]. This may explain how DCF and CIP combination are responsible for hepatotoxicity.

## 5. Conclusion

DCF and CIP induced hepatorenal injuries by affecting CYP450 gene expressions and inducing histopathological alterations. Meanwhile, co-administration of CIP could attenuate enterohepatic circulation of DCF and alleviated DCF-induced enteropathy in rats [16]. The medical use of both drugs, therefore, should be limited or co-ameliorated by natural vitamins or antioxidants.

## Conflict of Interest

Authors declare that they have no conflict of interest.



## References

1. Kelleni MT. Early use of non-steroidal anti-inflammatory drugs in COVID-19 might reverse pathogenesis, prevent complications and improve clinical outcomes. *Biomedicine & Pharmacotherapy*. 2021 Jan 1;133:110982. <https://doi.org/10.1016/j.biopha.2020.110982>
2. Altman R, Bosch B, Brune K, Patrignani P, Young C. Advances in NSAID development: evolution of diclofenac products using pharmaceutical technology. *Drugs*. 2015 May;75(8):859-77. <https://doi.org/10.1007/s40265-015-0392-z>
3. Mishra N, Mahamuni A. A COMPARATIVE STUDY OF DICLOFENAC SODIUM WITH PIROXICAM IN PATIENTS UNDERGOING SURGICAL REMOVAL OF THIRD MOLAR. *Journal of Critical Reviews*. 2020;7(7):669-71. <https://doi.org/10.31838/jcr.07.07.122>
4. Ptaszyńska N, Gucwa K, Olkiewicz K, Heldt M, Serocki M, Stupak A, Martynow D, Dębowski D, Gitlin-Domagalska A, Lica J, Łęgowska A. Conjugates of ciprofloxacin and levofloxacin with cell-penetrating peptide exhibit antifungal activity and mammalian cytotoxicity. *International journal of molecular sciences*. 2020 Jan;21(13):4696. <https://doi.org/10.3390/ijms21134696>.
5. Jaber DF, Jallad MA, Abdelnoor AM. The effect of ciprofloxacin on the growth of B16F10 melanoma cells. *Journal of cancer research and therapeutics*. 2017 Oct 1;13(6):956.
6. Eticha T, Kahsay G, Asefa F, Hailu T, Gebretsadik H, Gebretsadikan T, Thangabalan B. Chemometric-Assisted spectrophotometric method for the simultaneous determination of ciprofloxacin and doxycycline hyclate in pharmaceutical formulations. *Journal of analytical methods in chemistry*. 2018 Dec 18;2018. <https://doi.org/10.1155/2018/9538435>.
7. Phang-Lyn S, Llerena VA. *Biochemistry, Bio-transformation*. StatPearls [Internet]. 2020 Sep 2.
8. Raunio H, Kuusisto M, Juvonen RO, Pentikäinen OT. Modeling of interactions between xenobiotics and cytochrome P450 (CYP) enzymes. *Frontiers in pharmacology*. 2015 Jun 12;6:123. <https://doi.org/10.3389/fphar.2015.00123>
9. Matias M, Canário C, Silvestre S, Falcão A, Alves G. Cytochrome P450-mediated toxicity of therapeutic drugs. *Cytochrome P450 Enzymes: Biochemistry, Pharmacology and Health Implications*. 2014:13-50.
10. Ohshima K, Murayama N, Shimizu M, Yamazaki H. Drug interactions of diclofenac and its oxidative metabolite with human liver microsomal cytochrome P450 1A2-dependent drug oxidation. *Xenobiotica*. 2014 Jan 1;44(1):10-6. <https://doi.org/10.3109/00498254.2013.806837>.
11. Sychev DA, Ashraf GM, Svistunov AA, Maksimov ML, Tarasov VV, Chubarev VN, Otdelenov VA, Denisenko NJ, Barreto GE, Aliev G. The cytochrome P450 isoenzyme and some new opportunities for the prediction of negative drug interaction in vivo. *Drug design, development and therapy*. 2018;12:1147. <https://doi.org/10.2147/DDDT.S149069>.
12. Tornio A, Filppula AM, Niemi M, Backman JT. Clinical studies on drug–drug interactions involving metabolism and transport: methodology, pitfalls, and interpretation. *Clinical Pharmacology & Therapeutics*. 2019 Jun;105(6):1345-61. <https://doi.org/10.1002/cpt.1435>.
13. Deodhar, M., Al Rihani, S. B., Arwood, M. J., Darakjian, L., Dow, P., Turgeon, J., & Michaud, V. (2020). Mechanisms of CYP450 inhibition: understanding drug-drug interactions due to mechanism-based inhibition in clinical practice. *Pharmaceutics*, 12(9), 846. <https://doi.org/10.3390/pharmaceutics12090846>.



14. Spina E, Barbieri MA, Cicala G, de Leon J. Clinically relevant interactions between atypical antipsychotics and anti-infective agents. *Pharmaceuticals*. 2020 Dec;13(12):439. <https://doi.org/10.3390/ph13120439>.
15. Li Y, Meng Q, Yang M, Liu D, Hou X, Tang L, Wang X, Lyu Y, Chen X, Liu K, Yu AM. Current trends in drug metabolism and pharmacokinetics. *Acta Pharmaceutica Sinica B*. 2019 Nov 1;9(6):1113-44. <https://doi.org/10.1016/j.apsb.2019.10.001>.
16. Zhong ZY, Sun BB, Shu N, Xie QS, Tang XG, Ling ZL, Wang F, Zhao KJ, Xu P, Zhang M, Li Y. Ciprofloxacin blocked enterohepatic circulation of diclofenac and alleviated NSAID-induced enteropathy in rats partly by inhibiting intestinal  $\beta$ -glucuronidase activity. *Acta Pharmacologica Sinica*. 2016 Jul;37(7):1002-12. <https://doi.org/10.1038/aps.2016.54>
17. Aydin G, Gökçimen A, Öncü M, Çicek E, Karahan N, Gökalp O. Histopathologic changes in liver and renal tissues induced by different doses of diclofenac sodium in rats. *Turkish journal of veterinary and animal sciences*. 2003 Oct 15;27(5):1131-40.
18. Adeyemi WJ, Olayaki LA. Diclofenac-induced hepatotoxicity: Low dose of omega-3 fatty acids have more protective effects. *Toxicology reports*. 2018 Jan 1;5:90-5. <https://doi.org/10.1016/j.toxrep.2017.12.002>.
19. Alabi QK, Akomolafe RO. Kolaviron diminishes diclofenac-induced liver and kidney toxicity in wistar rats via suppressing inflammatory events, upregulating antioxidant defenses, and improving hematological indices. *Dose-Response*. 2020 Mar 2;18(1):1559325819899256. <https://doi.org/10.1177/1559325819899256>
20. Sharef AY, Hamdi BA, Alnajjar ZA. Histopathological aspects of co-administration of dexamethasone and diclofenac sodium on male albino rats. *Zanco Journal of Medical Sciences (Zanco J Med Sci)*. 2020 Aug 30;24(2):236-45. <https://doi.org/10.15218/zjms.2020.028>
21. SABEEH SI, SALIH RA, BDEWI SY, HASAN MS. Effects of ciprofloxacin on liver and kidney functions and histopathological features in rats. *International Journal of Pharmaceutical Research*. 2019 Oct;11(1).
22. Dogan Z, Elbe H, Taslidere EL, Soysal H, Cetin AY, Demirtas S. Effects of ciprofloxacin on fetal rat liver during pregnancy and protective effects of quercetin. *Biotechnic & Histochemistry*. 2017 Oct 3;92(7):481-6. <https://doi.org/10.1080/10520295.2017.1356469>
23. Buschmann J. The OECD guidelines for the testing of chemicals and pesticides. *Teratogenicity testing*. 2013:37-56. [https://doi.org/10.1007/978-1-62703-131-8\\_4](https://doi.org/10.1007/978-1-62703-131-8_4)
24. Abd El-Rhaman HA, Mohamed ZA, Sultan AR, Tawfik AR. Assessment of the Effect of Non-steroidal Anti-inflammatory Drug (Diclofenac Potassium) on the Pregnant Rats and their Fetuses.
25. Ravishankar AC, Gandigawad P, Hiremath SV. EFFECT OF CIPROFLOXACIN ON ACUTE AND SUBACUTE INFLAMMATORY RESPONSES IN WISTAR RATS.
26. Ibrahim ZS, Ahmed MM, El-Shazly SA, Alkafafy ME. Effects of camel milk on drug metabolising cytochrome p450 enzymes expressions in rats. *Journal of Camel Practice and Research*. 2016;23(1):25-32. <https://doi.org/10.5958/2277-8934.2016.00004.7>.
27. Livak KJ, Schmittgen TD. Analysis of relative gene expression data using real-time quantitative PCR and the  $2^{-\Delta\Delta CT}$  method. *Methods*. 2001 Dec 1;25(4):402-8. <https://doi.org/10.1006/meth.2001.1262>.
28. Coakes SJ, Steed L. *SPSS: Analysis without anguish using SPSS version 14.0 for Windows*. John Wiley & Sons, Inc.; 2009 Sep 30.



29. Zanger UM, Schwab M. Cytochrome P450 enzymes in drug metabolism: regulation of gene expression, enzyme activities, and impact of genetic variation. *Pharmacology & therapeutics*. 2013 Apr 1;138(1):103-41. <https://doi.org/10.1016/j.pharmthera.2012.12.007>.
30. Ansele JH, Thakker DR. High-throughput screening for stability and inhibitory activity of compounds toward cytochrome P450-mediated metabolism. *Journal of pharmaceutical sciences*. 2004 Feb 1;93(2):239-55. <https://doi.org/10.1002/jps.10545>.
31. Chopra N, Ruan CJ, McCollum B, Ognibene J, Shelton C, de Leon J. High doses of drugs extensively metabolized by CYP3A4 were needed to reach therapeutic concentrations in two patients taking inducers. *Revista Colombiana de Psiquiatría (English ed.)*. 2020 Apr 1;49(2):83-94. <https://doi.org/10.1016/j.rcpeng.2020.04.002>.
32. Daly AK, Rettie AE, Fowler DM, Miners JO. Pharmacogenomics of CYP2C9: functional and clinical considerations. *Journal of personalized medicine*. 2018 Mar;8(1):1. <https://doi.org/10.3390/jpm8010001>
33. Miners JO, Birkett DJ. Cytochrome P450C9: an enzyme of major importance in human drug metabolism. *British journal of clinical pharmacology*. 1998 Jun;45(6):525-38. <https://doi.org/10.1046/j.1365-2125.1998.00721.x>
34. Iqbal Z, Khan A, Naz A, Khan JA, Khan GS. Pharmacokinetic interaction of ciprofloxacin with diclofenac. *Clinical drug investigation*. 2009 Apr;29(4):275-81. <https://doi.org/10.2165/00044011-200929040-00006>
35. Bhogaraju A, Nazeer S, Al-Baghdadi Y, Rahman M, Wrestler F, Patel N. Diclofenac-associated hepatitis. *Southern medical journal*. 1999 Jul 1;92(7):711-3. <https://doi.org/10.1097/00007611-199907000-00011>
36. Rossi E, Ferraccioli GF, Cavalieri F, Menta R, Dall'Aglio PP, Migone L. Diclofenac-associated acute renal failure. *Nephron*. 1985;40(4):491-3. <https://doi.org/10.1159/000183528>.
37. Alan C, Koçoğlu H, Ersay AR, Ertung Y, Kurt HA. Unexpected severe hepatotoxicity of ciprofloxacin: two case reports. *Drug and chemical toxicology*. 2011 Apr 1;34(2):189-91. <https://doi.org/10.3109/01480545.2010.495392>.
38. George MJ, Dew RB, Daly JS. Acute renal failure after an overdose of ciprofloxacin. *Archives of internal medicine*. 1991 Mar 1;151(3):620-https://doi.org/10.1001/archinte.1991.00400030146039
39. Aydın G, Gökçimen A, Öncü M, Çicek E, Karahan N, Gökalp O. Histopathologic changes in liver and renal tissues induced by different doses of diclofenac sodium in rats. *Turkish journal of veterinary and animal sciences*. 2003 Oct 15;27(5):1131-40.
40. Baykal A, Sarigül F, Süleymanlar G, Moreira PI, Perry G, Smith MA, Alicigüzel Y. Ciprofloxacin does not exert nephrotoxicity in rats. *American Journal of Infectious Diseases*. 2005(1: 3):145-8. <https://doi.org/10.3844/ajidsp.2005.145.148>
41. Başaran A, Erol K, Başaran N, Güneş HV, Acikalın E, Timuralp G, Değirmenci I, Çakmak EA, Tomatir AG. Effects of ciprofloxacin on chromosomes, and hepatic and renal functions in rats. *Chemotherapy*. 1993;39(3):182-8. <https://doi.org/10.1159/000239124>
42. Feng S, He X. Mechanism-based inhibition of CYP450: an indicator of drug-induced hepatotoxicity. *Current drug metabolism*. 2013 Nov 1;14(9):921-45. <https://doi.org/10.2174/138920021131400114>.

