

جامعة نايف العربية للعلوم الأمنية
Naif Arab University for Security Sciences

Naif Arab University for Security Sciences
Arab Journal of Forensic Sciences & Forensic Medicine

www.nauss.edu.sa
http://ajfsfm.nauss.edu.sa



الجمعية العربية للعلوم الألة الجنائية والطب الشرعي
Arab Society for forensic Sciences and forensic Medicine

Sex Prediction using Foramen Magnum and Occipital Condyles Computed Tomography Measurements in Sudanese Population

Usama Mohamed El- Barrany¹, Sherin Salah Ghaleb¹, Samah Fathy Ibrahim^{1*}
Mohamed Nouri², Ali Hassan Mohammed³

¹ Forensic Medicine and Clinical Toxicology- Cairo University, Egypt.

² Specialist of Forensic Medicine –Ministry of Health, Sudan.

³ Specialist of Radiology –Ministry of Health, Sudan.

Received 12 April, 2016; Accepted 01 Dec. 2016; Available Online 30 Dec. 2016

Open Access



Abstract

Sex determination is important in establishing the identity of an individual. The foramen magnum is an important landmark of the skull base. The present research aimed to study the value of foramen magnum measurements to determine sex using computed tomography (CT) among Sudanese individuals.

Foramen magnum CT scans of 400 Sudanese individuals (200 males and 200 females) aged 18 - 83 years were included in this study. Foramen magnum (length and width), right occipital condyle (length and width), left occipital condyle (length and width), min-

imum intercondylar distance, maximum bicondylar distance and maximum medial intercondylar distance were measured. All data were subjected to discriminant functions analysis.

All nine measurements were significantly higher in males than females. Among these measurements, the right condyle length, minimum intercondylar distance and foramen magnum width were able to determine sex in Sudanese individuals with an accuracy rate of 83 %.

التنبؤ عن الجنس عند أفراد المجتمع السوداني عن طريق
الثقب العظمي (الكبرى) واللحمة القذالية (لحمة مؤخر
الرأس) باستخدام قياسات التصوير المقطعي المحوسب

المستخلص

يعد تحديد الجنس ذو أهمية بالغة في الاستعراف على هوية الأفراد. وتشكل الثقب العظمي (foramen magnum) معلماً مهماً في قاعدة الجمجمة. ويهدف هذا البحث إلى دراسة قيم قياسات الثقب العظمي في التنبؤ عن الجنس باستخدام التصوير المقطعي المحوسب (CT) عند أفراد من المجتمع السوداني. وقد أجريت

Keywords: Forensic Science, Forensic Anthropology, Foramen Magnum, Computed Tomography, Discriminate Functional Analysis, Sudanese Population.

* Corresponding Author: Samah Fathy Ibrahim
Email:samahibraheem@yahoo.com

1658-6794© 2016 AJFSFM. This is an open access article distributed under the terms of the Creative Commons Attribution-NonCommercial License.

doi: 10.12816/0033135



Production and hosting by NAUSS

الدراسة بعمل مسح بالتصوير المقطعي المحوسب للثقب العظمي لأربعمئة سوداني تتراوح أعمارهم بين 18-83 سنة، منهم مئتان من الذكور ومثلهم من الإناث. وتم أخذ قياسات الثقب العظمي من حيث الطول والعرض، والمسافة القذالية اليمنى واليسرى من حيث الطول والعرض، والمسافة الحدية الصغرى بين اللقمتين، والمسافة الحدية الكبرى بين اللقمتين، والمسافة القصوى ثنائي اللقمة. تم إخضاع جميع البيانات لتحليل وظائف التمايز. وكانت جميع القياسات التسعة بالدلالة الإحصائية أعلى عند الذكور منها عند الإناث. ومن بين هذه القياسات، كان كل من قياس طول اللقمة اليمنى، والمسافة الحدية الصغرى المسافة بين اللقمتين وعرض الثقب العظمي قادرة على تحديد الجنس في أفراد المجتمع السوداني مع معدل دقة وصل إلى 83%.

الكلمات المفتاحية: الأدلة الجنائية، علم الإنسان، الثقب العظمي، التصوير المقطعي المحوسب، تحليل وظائف التمايز، المجتمع السوداني.

1. Introduction

Forensic anthropology has been one of the fastest growing medico-legal disciplines due to its invaluable, contribution and services to law enforcement agencies and criminal justice [1]. It offers help in the identification of deceased individuals whose remains are burned, mutilated, decomposed or otherwise unrecognizable. Using physical markers present on a skeleton, a forensic anthropologist can possibly ascertain a victim's age, sex, stature, and ancestry. Additionally, forensic anthropologists can make use of skeletal abnormalities to potentially determine cause of death, past trauma such as broken bones or medical procedures, as well as diseases such as bone cancer [2].

Accurate sex determination is an important and one of the foremost criteria in establishing the identity of an individual [3]. Numerous studies have been conducted and are in progress in many parts of the world for sex determination from different human bones, i.e. skull, pelvis, long bones and scapula that are often recovered either in a

fragmented or mutilated form [4]. Sex determination is also done through measuring certain bone dimensions, e.g., the foramen magnum (FM) and the occipital condyles, and then subjecting these measurements to the discriminant function analysis as a statistical model in sex determination [5].

The FM is an opening in the occipital bone through which the cranial cavity communicates with the vertebral canal. The occipital condyles lie lateral to each side of the FM [6].

Advances in modern technologies such as computed tomography (CT) scanning, Magnetic Resonance Imaging (MRI) and computer-based anthropometry have significantly improved the accuracy of skeletal analyses, especially in sex determination [7].

The purpose of this study was to evaluate the ability of using the FM dimensions alone or in combination with the occipital condyles measurements in sex determination using high resolution multi-slice CT scans among the Sudanese population.

2. Materials and Methods

This is a cross-sectional study which was conducted on randomly selected Sudanese individuals, who visited the Antalia Radiology Center (Sudan) between January and October 2013 for medical reasons. A sample of 400 high-resolution multi-slice CT scans of the head was evaluated to record 9 measurements of the FM and occipital condyles in individuals aged 18 - 83 years. The studied group consisted of 200 males and 200 age-matched females. Prior approval was obtained from the Antalia Radiology Center ethics committee to conduct this research (Ref. code: 121-9/11/2012). Patients with history of trauma, surgery, pathological lesions or poor image quality in the region of the FM were excluded from the study.



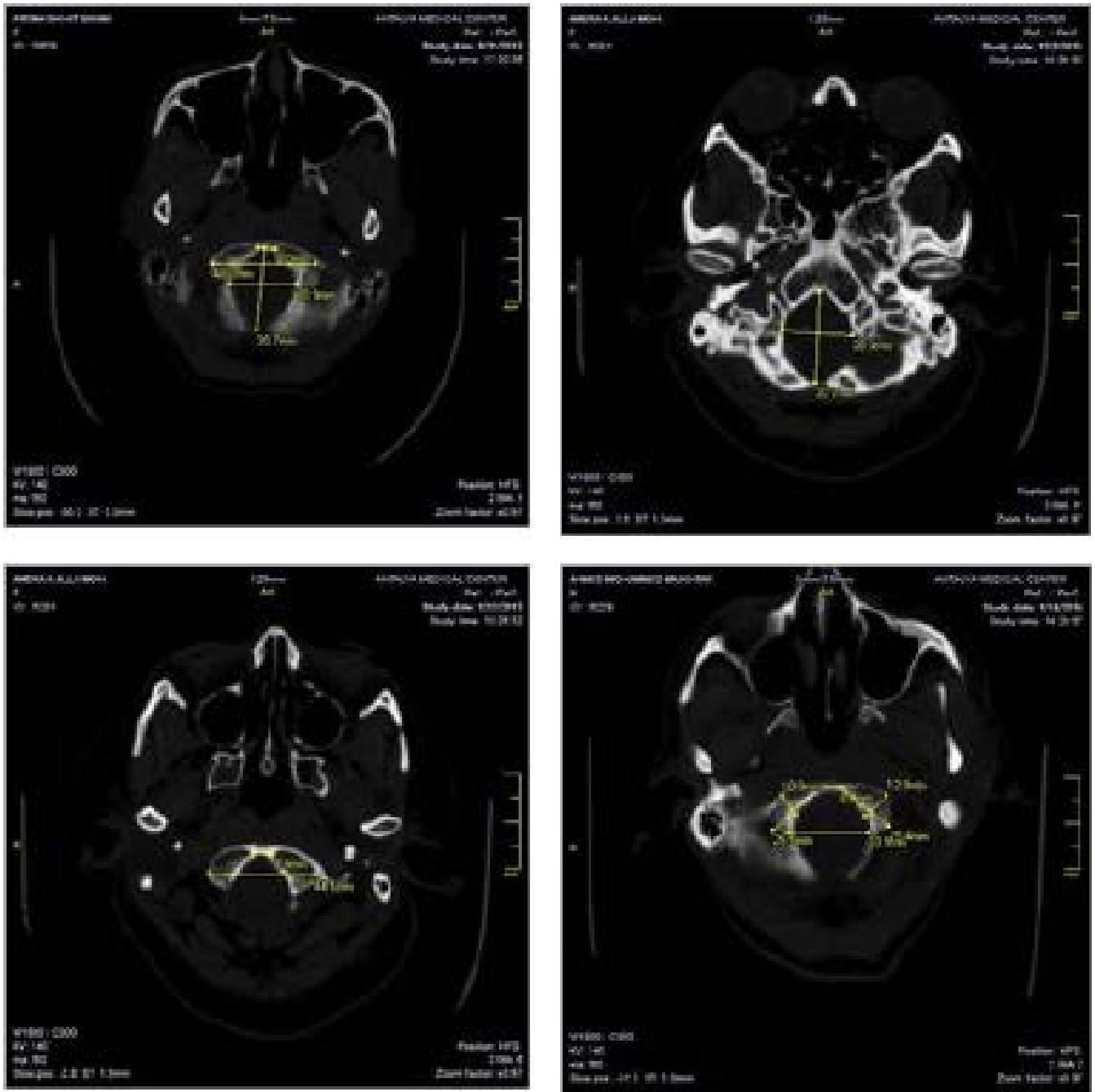


Figure 1- Foramen magnum CT images showing studied parameters.

2.1 Radiographic measurements

The measurements were recorded by a trained radiologist on high-resolution multi-slice CT. The authors used a Bright Speed device (General Electric Healthcare Company, India) that produces high-quality diagnostic images, with built-in solutions to accelerate acquisition, processing, transfer, high productivity by adjusting window width/win-

dow level (WW/WL) values for single-bundle versus double-bundle reconstruction. K-PACS V 1.6.0 image viewer (Image Information System Ltd, Copyright 2007, UK) was used for viewing and manipulating DICOM images, making measurements and converting them into several image formats. This software manages large thick-slice data sets easily and quickly. The images were reconstructed and

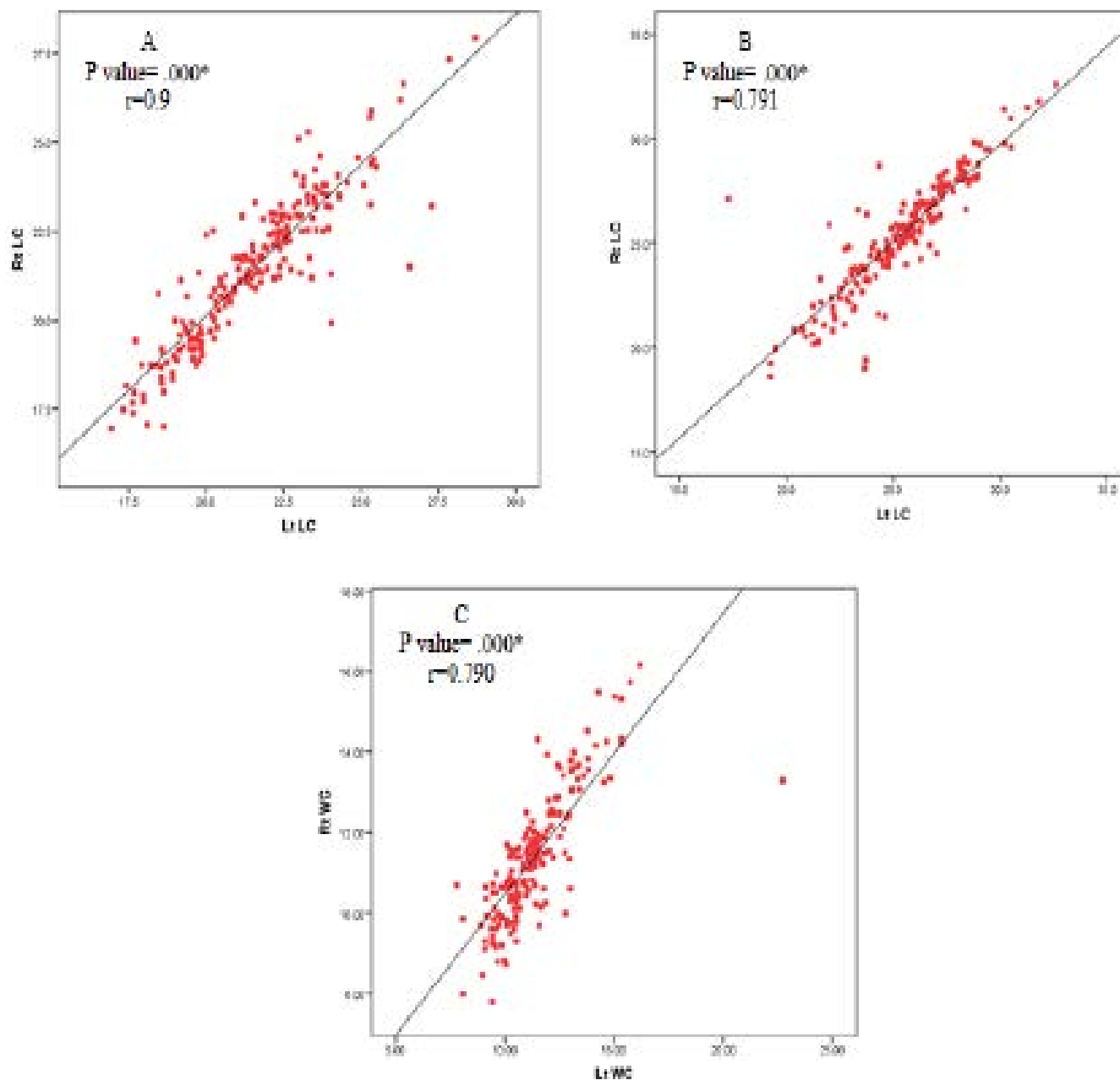


Figure 2- Correlation between A: Length of Right Condyle (LRC) and Length of Left Condyle (LLC) among the female group, B: between Length of Right Condyle (LRC) and Length of Left Condyle (LLC) among the male group. C: Width of Right Condyle (WRC) and Width of Left Condyle (WLC) among the male group.

viewed on the scanner's workstation using the appropriate software package. Nine dimensions were measured, and these measurements were obtained from the reconstructed images by the same person. Measurements were repeated in triplicate and the mean was recorded:

1. Minimum intercondylar distance (MnID): The minimum distance between the medial edges of the ar-

ticular surfaces of the condyles (D1-D2) (Figure-1).

2. Maximum bicondylar distance (MBD): The bicondylar breadth; the maximum distance between the lateral edges of the articular surfaces of the condyles (C1-C2) (Figure-1).
3. Maximum medial intercondylar distance (MID): The intercondylar breadth; the maximum distance

Table 1- Mean values of the nine measurements and their significance among the Sudanese population.

Variables Measurement (mm)	Male (n=200)		Female (n=200)		t-test for equality of means	
	Mean±SD	Min-Max	Mean±SD	Min-Max	test statistic	Sig. (2-tailed)
Minimum Intercondylar Distance (MnID)	10.49±2.63	5.20 - 19.60	9.62±2.15	4.40 - 15.37	3.643	0.000*
Maximum Bicondylar Distance (MBD)	48.90±4.73	31.20 - 59.60	46.89±4.02	27.61 - 57.00	4.576	0.000*
Maximum Medial Intercondylar Distance (MMID)	27.20±2.74	19.48- 37.30	25.46±2.50	18.26 - 33.19	6.608	0.000*
Length of the Foramen Magnum (LFM)	38.54±3.22	27.32 - 49.70	37.05±2.99	30.04 - 45.50	4.805	0.000*
Width of the Foramen Magnum (WFM)	31.57±2.62	24.5 - 38.6	30.33±2.46	23.5 - 38.2	4.873	0.000*
Length of Right Occipital Condyle (LRC)	25.52±2.68	18.6 - 32.6	21.41±2.05	17.0 - 27.9	17.203	0.000*
Length of Left Occipital Condyle (LLC)	25.40±3.04	17.30 - 32.6	21.50±2.19	16.9 - 28.7	14.712	0.000*
Width of Right Condyle (WRC)	11.39±1.51	7.80 - 16.16	10.62±1.34	7.66 - 16.37	5.421	0.000*
Width of Left Condyle (WLC)	11.33±1.71	7.81 - 22.72	10.38±1.33	6.35 - 17.78	6.204	0.000*

SD; standard deviation, * significant $p > 0.001$; Min=Minimum, Max=maximum.

Table 2- Canonical discriminant function coefficients among the nine measurements.

Measurements	Function
	1
Minimum Intercondylar Distance (MnID)	0.159
Width of the Foramen Magnum (WFM)	0.063
Length of Right Condyle (LRC)	0.406
Constant	-13.080



Table 3- The accuracy of the function analysis to predict sex among the Sudanese population.

Sex	Predicted Group Membership	
	Male	Female
Male (n=200)	162	38
Female (n=200)	25	175
Male (100%)	81.0	19.0
Female (100%)	12.5	87.5

Table 4- Fisher's linear discriminant function analysis demonstrating the statistically significant three lines.

Measurements	Sex	
	Male	Female
Minimum Intercondylar Distance (MnID)	2.690	2.391
Width of the Foramen Magnum (WFM)	4.413	4.294
Length of Right Condyle (LRC)	4.504	3.744
Threshold Constant (c)	-141.897	

between the medial articular margins of the condyles (E1-E2) (Figure-1).

4. Length of the foramen magnum (LFM): The maximum internal length of the foramen magnum along the midsagittal plane (A1-A2) (Figure-1).
5. Width of the foramen magnum (WFM): The maximum internal width of the foramen magnum perpendicular to the midsagittal plane (B1-B2) (Figure-1).
6. Length of right occipital condyle (LRC): The maximum length of right condyle along the long axis from the edges of the articular surface (A1-A2) (Figure-1).
7. Length of left occipital condyle (LLC): The maximum length of left condyle along the long axis from the edges of the articular surface (B1-B2) (Figure-1).
8. Width of right occipital condyle (WRC): The maxi-

imum width of right condyle from the articular edges along a line perpendicular to the long axis (C1-C2) (Figure-1).

9. Width of left occipital condyle (WLC): The maximum width of left condyle from the articular edges along a line perpendicular to the long axis (D1-D2) (Figure-1).

2.2 Statistical analysis

All statistical data were analyzed using SPSS for Windows, version 18 (statistical package for social science, Chicago, Illinois, USA). Mean and standard deviations were obtained for all measurements. The Pearson's correlation coefficient between variables in both sexes was calculated. Student's t-test was used to quantify the difference between the male and female measurements. A p-value of ≤ 0.05 was considered significant. Fisher's linear and canonical discriminant functions analysis were performed to



identify sex predictor variables. From these analyses, coefficients and constants were obtained for deriving discriminant function equations. The bone was classified as female if the value of the female equation was greater than the male and vice versa.

3. Results

The study included 400 subjects (200 males and 200 females) aged 18-83 years. Regarding the age distribution of the studied population, there was no significant difference among different age groups (p value >0.05).

Table-1 shows that nine measurements of FM and occipital condyles were significantly greater in males than in females.

Pearson's correlation was applied for all measurements. Among the female group, the strongest positive correlation was between LLC/LRC ($r=0.9$; Figure 2-A). While in the male group, the strongest positive correlation was between LLC/ LRC ($r= 0.791$; Figure 2-B) and WLC/ WRC ($r= 0.790$, Figure 2-C).

Table-2 and Table-3 show the discriminant function analysis among the nine variables, where the canonical correlation was 0.684, with MnID, LRC and WFM emerging as the main predictor variables of sex determination. They could correctly classify 84.3% of the cases examined; males were correctly classified 81 % of the time and females were correctly classified 87.5 % of the time.

Table-4 shows Fisher's linear discriminant function analysis. The equations, provided by this analysis, were used to calculate D^{male} and D^{female} as follows:

$$D^{\text{male}} [(4.504 \times \text{RLC}) + (4.413 \times \text{WFM}) + (2.690 \times \text{MnID})] - 141.897$$

$$D^{\text{female}} [(0.744 \times \text{RLC}) + (4.294 \times \text{WFM}) + (2.391 \times \text{MnID})] - 117.403$$

The bone is classified as female if the value of D^{female} is greater than the value of D^{male} and vice versa.

4. Discussion

Sex determination sets the stage for other demographic factors to be determined. However, it can be a very difficult exercise in the absence of a complete skeleton. Thus, researchers have attempted and used metric variables from intact and fragmentary skeletal materials in the derivation of discriminant function equations. Craniometric measurements can be used to identify an individual from a skull found detached from its skeleton [8].

Nine measurements of FM and occipital condyles were significantly greater in males than in females. These results indicated the presence of significant sexual dimorphism on examining the CT scans.

The LFM was greater in males than females, 38.54 ± 3.22 mm versus 37.05 ± 2.99 mm, respectively. This result was in agreement with Uthman et al. [5] who found that LFM was also higher in males (34.9 ± 2 mm) than females (32.9 ± 2 mm) in the Turkish population. On the contrary, Singh and Talwar [9] reported that LFM was insignificant in predicting sex among Indian population.

In this study, WFM was also higher in males than females (31.57 ± 2.6 mm versus 30.33 ± 2.5 mm). This is in agreement with the findings of Uthman et al. [5] and Gopalrao et al. [10]; however, WFM values reported in the present study were much higher than Uthman et al. [5]. This difference in WFM may be due to normal individual variations or using a different measurement technique in their study (helical CT).

Results of this study showed that both LRC (25.52 ± 2.68 mm) and LLC (25.40 ± 3.04 mm) in males were significantly higher ($p=0.000$) than LRC (21.41 ± 2.05 mm) and LLC (21.50 ± 2.19 mm) in females. Condyle's lengths reported in



this study were in conformity with the lengths reported by Bello et al. [11] and Kumar et al. [12], who found that the LRC in Indian dry skulls was 23.88 ± 1.5 mm for males and 22.6 ± 1.30 mm for females, whereas the LLC was 24.99 ± 1.82 mm for males and 24.20 ± 1.62 mm for females. However, results reported in this study were in disagreement with Lang and Hornung [13], who studied these measurements in the German population. This may be due to differences in geographical location and ethnicity.

In the present study, the measured WRC and WLC in males and females were as follows: 11.39 ± 1.51 mm, 10.62 ± 1.34 mm, 11.33 ± 1.71 mm and 10.38 ± 1.33 mm, respectively. Kumar and Nagar [12] reported higher WRC and WLC values. They found that the mean WRC in the Indian male and female was 12.97 ± 1.43 mm and 11.65 ± 1.33 mm, whereas WLC was 14.11 ± 1.01 mm and 13.85 ± 1.02 mm, respectively.

Results reported in this study showed that the measured MBD was 48.90 ± 4.73 mm in males and 46.89 ± 4.02 mm in females. Contrary to this study, mean MBD reported by Gapert et al. [14] was slightly higher in British males (51.29 mm) and females (48.67 mm). Wescott and Morre Jansen [15], who studied foramen magnum among the African–American population, found that the mean MBD in black males and females was 49.6 mm and 47.3 mm, respectively; and among white males and females it was 51.9 mm and 49.8 mm, respectively which was slightly higher than reported in the present study. This may be due to the difference in the type of study sample and measurement techniques. The said authors used dried skulls and took the measurements manually [15].

The MnID in this studied Sudanese male and female population was 10.49 ± 2.63 mm and 9.62 ± 2.15 mm, respectively. Kumar and Nagar [12] reported a higher mean MnID score among Indian male (17.63 mm) and female

(17.30 mm) skulls. The lower values presented in the present study may be due to the application of different measuring and analysis methodologies.

In this study, the mean MID was 27.20 ± 2.74 mm in males and 25.46 ± 2.50 mm for females, which is in accordance with the study carried out by Singh and Talwar [9], who reported that the mean MID in Indian males and females was 26.15 ± 3.31 mm and 24.71 ± 4.57 mm, respectively.

Significant correlations were seen between LLC/LRC, WRC/WLC, MID/WFM and LFM/WFM among both males and females in this studied Sudanese population. This indicates a homogenous growth of males and females in this studied Sudanese population sample. This was not the case in Poland where Burdan et al. [16] studied the morphology of the foramen magnum in young Eastern European male ($n=142$) and female adults ($n=171$) using 3D computer tomography images. They found sexual dimorphism of the FM among their studied individuals, related mainly to its linear diameters and area but not to the shape. They also reported that female skulls had higher correlation between the examined parameters of the foramen magnum and proper external cranial measurements, indicating more homogeneous growth in females than males [16].

In the present study, among the nine examined measurement variables of FM, LRC, MnID and WFM emerged as the most significant parameters for the determination of sex in Sudanese population. These results are in partial agreement with Macaluso [17], who analyzed a skeletal sample of 68 French individuals (36 males and 32 females) with documented sex identification and found that WFM was a significant variable in sex prediction among the French population.

Results reported in this study also agree with Uysal et al. [18], who reported that both LRC and WFM were among the sex determining variables in the Indian popula-



tion. However, the authors also reported that WRC was a significant variable of sex determination in the Indian population [18]. Moreover, Singh and Talwar [9] found that MBD was also a reliable sex determining variable in the Indian population. These variations may be related to sample size, ethnicity, geographical origin and methodological differences.

Classification analysis revealed that LRC, MnID and WFM could determine sex with an accuracy rate of 83 %, which is higher than Uysal et al. [18] by 2%. Macaluso [17] found that the LLC and MnID had a low discriminatory power in sexual dimorphism in the French population with an accuracy rate of 67.7%. Moreover, Gapert et al. [14], who studied the FM diameters in the European population, did not find any sexual dimorphism to determine unknown sex.

5. Conclusion

Results reported in this study conclude that the FM is a very important anatomical landmark in sex determination among the Sudanese population. Morphometric analysis using modern radiological techniques such as CT increases the accuracy of sex prediction, and, moreover, decreases the need for defleshing and classical autopsy. Among all FM variables, the LRC, MnID and WFM could determine sex using specific equation with an accuracy rate of 83%. Further studies into different geographical regions and ethnic origins are recommended to have population specific data for estimating the sex of unknown individuals. Radiological support should provide the easiest measurements to improve the reliability of statistical analysis.

Conflict of interest statement

The authors have no conflicts to disclose.

References

1. İşcan MY, Olivera HE. Forensic anthropology in Latin America. *Forensic Sci Int* 2000;109:15-30.
2. Albanese J, Cardoso HF, Saunders SR. Universal methodology for developing univariate sample-specific sex determination methods: an example using the epicondylar breadth of the humerus. *J Archaeol Sci* 2005;32:143-2.
3. Krishan K, Kanchan T, Menezes RG, Ghosh A. Forensic anthropology casework—essential methodological considerations in stature estimation. *J Forensic Nurs* 2012;8:45-50.
4. İşcan MY. Forensic anthropology of sex and body size. *Forensic Sci Int* 2005;147:107-12.
5. Uthman AT, Al-Rawi NH, Al-Timimi JF. Evaluation of foramen magnum in gender determination using helical CT scanning. *Dentomaxillofac Radiol* 2014; 41: 197-202.
6. Nowinski WL, Thaug TS, Chua BC, Yi SH, Ngai V, Yang Y, Chrzan R, Urbanik A. Three-dimensional stereotactic atlas of the adult human skull correlated with the brain, cranial nerves, and intracranial vasculature. *J Neurosci Methods* 2015; 246:65-4.
7. Dedouit F, Telmon N, Costagliola R, Otal P, Joffre F, Rougé D. Virtual anthropology and forensic identification: report of one case. *Forensic Sci Int* 2007;173:182-7.
8. Ono I, Ohura T, Narumi E, Kawashima K, Matsuno I, Nakamura S, et al. Three-dimensional analysis of craniofacial bones using three-dimensional computer tomography. *J Craniomaxillofac Surg* 1992;20:49-60.
9. Singh G, Talwar I. Morphometric analysis of foramen magnum in human skull for sex determination. *Hum Biol Rev* 2013;2:29-4.



10. Gopalrao SR, Solanke P, Ugale M, Balsurkar S. Computed tomographic scan study of morphometry of foramen magnum. *Int J Curr Res Rev* 2013;5:41.
11. Bello SS, Zagga AD, Kalale SB, Usman JD, Bello A, Abdulhameed A et al. Measurements of Occipital Condyles using Computerised Tomography from Sokoto State, Nigeria. *Int J Health Med Inf* 2013; 2: 10-7
12. Kumar A, Nagar M. Human Adult Occipital Condyles: Morphometric Analysis. *Res Rev J Med Health Sci* 2014; 3: 112-6.
13. Lang J, Hornung G. The hypoglossal channel and its contents in the posterolateral access to the petroclival area. *Neurochirurgia* 1993;36:75-80.
14. Gapert R, Black S, Last J. Sex determination from the foramen magnum: discriminant function analysis in an eighteenth and nineteenth century British sample. *Int J Legal Med* 2009;123:25-3.
15. Wescott DJ, Moore-Jansen PH. Metric variation in the human occipital bone: forensic anthropological applications. *J Forensic Sci* 2001;46:1159-63.
16. Burdan F, Szumiło J, Walocha J, Klepacz L, Madej B, Dworzański W, Klepacz R, Dworzańska A, Czekajaska-Chehab E, Drop A. Morphology of the foramen magnum in young Eastern European adults. *Folia Morphol* 2012;71:205-16.
17. Macaluso Jr PJ. Metric sex determination from the basal region of the occipital bone in a documented French sample. *Bulletins et mémoires de la Société d'anthropologie de Paris* 2011;23:19-6.
18. Uysal SE, Gokharman D, Kacar M, Tuncbilek I, Kosa U. Estimation of sex by 3D CT measurements of the foramen magnum. *J Forensic Sci* 2005;50:1310-4.

