



Naif Arab University for Security Sciences  
Arab Journal of Forensic Sciences & Forensic Medicine

www.nauss.edu.sa  
http://ajfsfm.nauss.edu.sa



المجتمعة العربية للعلوم الجنائية والطب الشرعي  
Arab Society for Forensic Sciences and Forensic Medicine

# Radio-morphometric Analysis of Sella Turcica in the South Indian Population: A Digital Cephalometric Study

Ch. Sai Kiran<sup>\*1</sup>, P. Ramaswamy<sup>2</sup>, Santosh N<sup>2</sup>, B. Smitha<sup>2</sup>, Satish A<sup>2</sup>

Open Access

<sup>1</sup> Department of Oral Medicine and Radiology, GSL Dental College and Hospital, Rajahmundry, Andhra Pradesh, India

<sup>2</sup> Department of Oral Medicine and Radiology, St. Joseph Dental College, Eluru, Andhra Pradesh, India

Received 29 Nov. 2016; Accepted 30 Mar. 2017; Available Online 17 May. 2017



Original Article

## Abstract

The present study was undertaken to identify the role of radio-morphometric analysis of sella turcica in sex determination.

A total of 260 good quality lateral cephalograms (130 males and 130 females) were randomly selected from the orthodontic database between 2014 and 2015. Radiographic measurements (antero-posterior diameter and depth of sella) were carried out by a senior oral radiologist. The values obtained were tabulated in a spreadsheet and subjected to statistical analysis (SPSS version 16.0,

SPSS.inc, Chicago, 1989 – 2007).

A higher percentage of both males (70.0%) and females (67.7%) were presented with normal sella. The second best sella presentation was the shallow sella in males (16.2%). The mean antero-posterior diameter was higher in females (12.25 mm) than males (11.74 mm). The mean depth of sella turcica was greater in females (8.08 mm) than males (7.68 mm). Discriminant function analysis was done with gender as a grouping variable and antero-posterior dimensions and sella depth as independent variables. The formula obtained was  $D = 0.452(x) + 0.295(y) - 7.753$ . (Where “D” is the discriminant score, “x” is antero-posterior diameter of sella, “y” is sella depth). The present study revealed an overall accuracy rate of 58.1% in identifying correct gender using sella measurements.

The present study was the first of its kind in the South Indian population and has presented results that justify the use of sella turcica for sex determination.

**Keywords:** Forensic Science, Sella Turcica, Sex Dimorphism, Gender Identity, Lateral Cephalogram.

\* Corresponding Author: Ch. Sai Kiran,  
Email:: iamchennojukiran@gmail.com

1658-6794© 2017 AJFSFM. This is an open access article distributed under the terms of the Creative Commons Attribution-NonCommercial License.

doi: 10.26735/16586794.2017.019



Production and hosting by NAUSS

التحليل الراديوي المورفولوجي لعظم السرج التركي في الجمجمة

## عند سكان الهند الجنوبيين-دراسة رقمية لقياسات الرأس

### المستخلص

لقد أجريت الدراسة الحالية بهدف التعرف على دور التحليل الراديوي في قياس أبعاد عظم السرج التركي في تحديد الجنس. وقد اختير عشوائياً اختياراً ما مجموعه 260 صورة من صور قياسات الرأس ذات الدقة الجيدة لـ (130 ذكور و 130 إناث) من قاعدة بيانات تقويم الأسنان بين عامي 2014 و 2015. وقد أُجريت القياسات الشعاعية (للقطر الأمامي الخلفي وعمق السرج التركي من الجمجمة) من قبل طبيب الأشعة المختص عن طريق الفم. تمت جدولة القيم التي تم الحصول عليها في جدول بيانات وتم القيام بالتحليل الإحصائي باستخدام التطبيق SPSS، الإصدار رقم 16.0، المرخص من شركة SPSS inc، شيكاغو، لسنة (1989 - 2007). كانت هناك النسبة الأعلى لكل من الذكور (70.0%) والإناث (67.7%) تقيد بأن عظم السرج التركي في الجمجمة عادي. وكانت الفئة الثانية تظهر عظم السرج التركي في الجمجمة بعمق قليل في الذكور (16.2%). وكان متوسط قيم القطر الأمامي الخلفي أعلى بكثير لدى الإناث (12.25 ملم) منها في الذكور (11.74 ملم). كما أن متوسط قيم عمق السرج التركي كانت أكبر عند الإناث (8.08 ملم) منها عند الذكور (7.68 ملم). وقد تم التحليل الوظيفي التمييزي بين الجنسين بتثبيت المتغيرات، وجعل أبعاد القطر الأمامي الخلفي، وعمق عظم السرج التركي كمغيرات مستقلة. وكانت هذه الدراسة هي الأولى من نوعها في سكان جنوب الهند، وقدمت نتائجها المبرر العلمي لاستخدام عظم السرج التركي في تحديد الجنس.

الكلمات المفتاحية: علوم الأدلة الجنائية، عظم السرج التركي في الجمجمة، ازدواج الشكل الجنسي، تحديد جنس الشخص، ازدواج الشكل، صورة قياسات الرأس الجانبية.

The name sella turcica is derived from Latin which means "Turkish saddle" [1]. It is located in the middle cranial fossa and lies on the body of sphenoid. It consists of central pituitary fossa bounded anteriorly by tuberculum sella, posteriorly by dorsum sella and inferiorly by sphenoidal sinus. The sella is usually demarcated by a dense thin white curve on lateral cephalograms and acts as a noteworthy reference point. It is readily traceable for metric analysis, which makes it an excellent source of information for identification of pathologies related to the pituitary gland.

The anatomy of sella will vary in size and shape from person to person in different populations. Most of the studies related to sella shapes are on western populations. In this context, Zagga et al. insisted upon creating baseline database studies from indigenous population groups based on their ethnic origin [2].

The radiographic and morphometric variations of sella are mostly related to variations in growth, which plays a vital role in sex determination. Females have earlier and more prolonged growth spurts compared to males [3]. The pituitary gland enlarges during the period of active growth, causing sella to enlarge with it [4]. Moreover, the dimensions of sella can be successfully calculated using plane radiographs, which are highly economical from the patient's point of view [5]. Hence, the present study was undertaken to establish the normal dimensions of sella turcica in the South Indian population with the objective of identifying the role of radio-morphometric analysis of sella turcica in sex determination.

## 2. Materials and Methods

The study procedure was explained and institutional ethical committee approval was obtained (IRB NO: SJDC/RP/2016-07). A total of 260 good quality lateral cephalograms (130 males and 130 females) were randomly selected from the orthodontic database between 2014 and 2015. Informed consent was obtained from the patients before including them in the study. Necessary care was taken to



exclude patients with congenital defects in the craniofacial region like clefts and malformations, history of craniofacial fractures and patients suffering from disorders of bone, nutritional deficiencies and endocrinal disturbances. All the radiographs were taken using Orthophos digital panoramic machine (Orthophos, Sirona dental systems, GmbH, Germany) with the patient's Frankfort plane parallel to the floor.

The shape of sella turcica was classified according to the classification given by Axelsson et al., which includes six variants: (a) normal sella, (b) oblique anterior wall, (c) extremely low sella turcica, (d) sella turcica bridge, (e) irregularity (notching) in the posterior parts of the sella, and (f) pyramidal shape of the dorsum sella (Figure-1) [6].

Radiographic measurements were carried out using measuring tools of SIDEXIS XG software (2.53 versions, copyright © 2011 Sirona dental systems, Germany). The following measurements were obtained from the digital lateral cephalograms in sagittal plane using the method employed by Silverman et al. with a few modifications (Figure-2) [7]:

- a) Antero-posterior (A-P) diameter of sella turcica: the point below tuberculum sella and the anterior margin of dorsum sella. It is the greatest distance between the anterior wall and the posterior wall of sella.
- b) Depth of sella turcica: the distance from midpoint of tuberculum sella and dorsum sella to the floor of the sella.

The values obtained were tabulated in a spreadsheet and

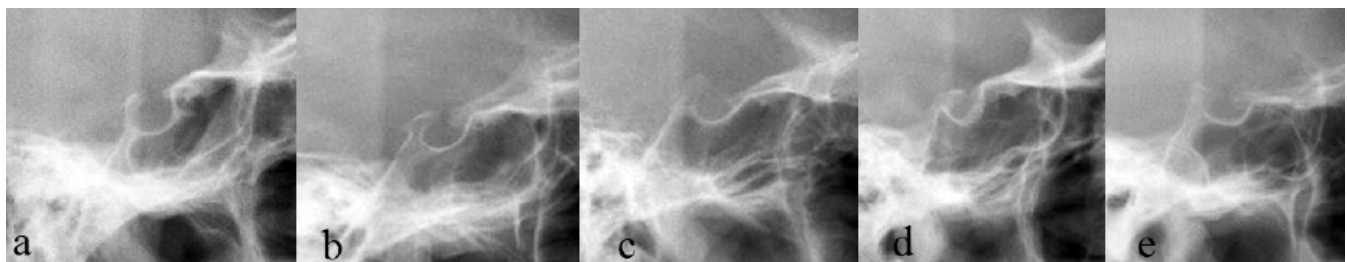
subjected to statistical analysis (SPSS version 16.0, SPSS, inc, Chicago, 1989 – 2007). The mean and standard deviation of the length and depth of sella were calculated. These values were compared for males and females using t-test. The variation in sella shape in both genders was evaluated using chi-squared test. Finally, the data was subjected to discriminant analysis, and the discriminant equation was drawn. A subset of 50 lateral cephalograms was reselected from the database and the measurements were repeated by the same observer after a period of 1 week to evaluate the intraobserver variability.

### 3. Results

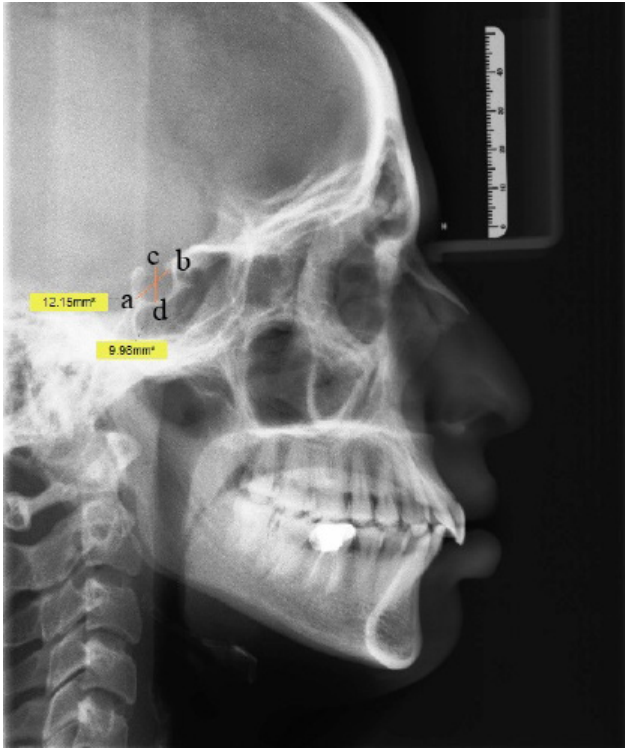
A total of 260 radiographs were included in the study (130 males and 130 females) between the age groups of 10 to 61 years. The shape of sella was evaluated and measurements were made by an experienced oral radiologist. The maximum A-P diameter, sella depth and sella ratio were calculated in the lateral cephalograms.

The majority of the males (70.0%) and females (67.7%) had normal sella shape. The second best sella presentation was shallow sella in males (16.2%). Interestingly, shallow sella and oblique anterior sella shapes shared the same percentages in females (13.1%). But chi-squared test revealed no significant differences between groups (Table-1).

The mean A-P diameter was significantly higher in females (12.25 mm) than males (11.74 mm) ( $p < 0.01$ ). The mean depth of sella turcica was greater in females (8.08 mm) than males (7.68 mm). Scatter plots depicting the distribution of measurements in males and females are shown



**Figure 1-** Different shapes of sella observed in the study. (a) Normal sella, (b) Irregular sella, (c) Anterior oblique sella, (d) Pyramidal sella, (e) Shallow sella.



**Figure 2-** Antero-posterior diameter of sella turcica (point a – point b): It is the point below tuberculum sella and the anterior margin of dorsum sella. It is the greatest distance between anterior wall and posterior wall of sella. Depth of sella turcica (point c – point d): This is the distance from midpoint of tuberculum sella and dorsum sella to the floor of the sella.

in Figure-3 & 4. No significant difference was observed in the mean values of sella ratio between males and females (Table-2). A subset of 30 radiographs were randomly selected and re-evaluated by the same examiner after 2 weeks. The intra class correlation coefficient was observed to be 0.993 for antero-posterior dimensions and 0.998 for depth measurements (Table-3).

In the present study, significant Wilk's lambda values were produced only by antero-posterior diameter and sella depth measurements (Table-4). The results indicate that these variables are better indicators for sex determination when compared to sella ratio. Hence, discriminant function analysis was done with gender as a grouping variable and antero-posterior dimensions and sella depth measurements as independent variables.  $D = 0.452(x) + 0.295(y) - 7.753$ . [Where "D" is the discriminant score, "x" is A-P diameter

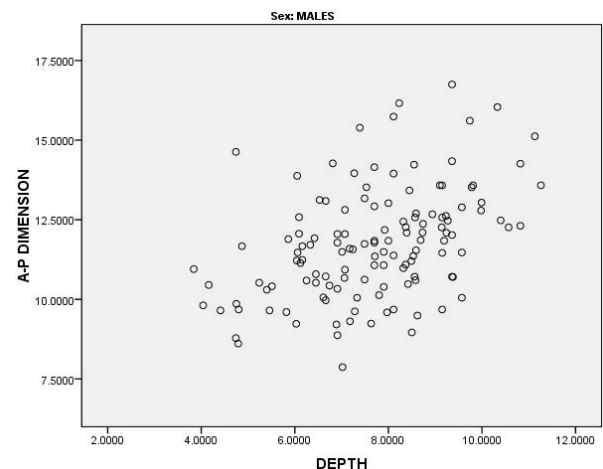
of sella (mm), "y" is sella depth (mm)].

The discriminant equation was applied to the study sample, which showed a higher percentage of accuracy in identifying females (58.5%), than males (57.7%), with an overall accuracy rate of 58.1% (Table-5). The present study revealed an overall sensitivity of 49.6% and specificity of 49.5% in identifying the correct gender using radiometric analysis of sella. A higher positive predictive value of 57.7% was recorded in the study, when compared to negative predictive value of 41.5% (Table-6).

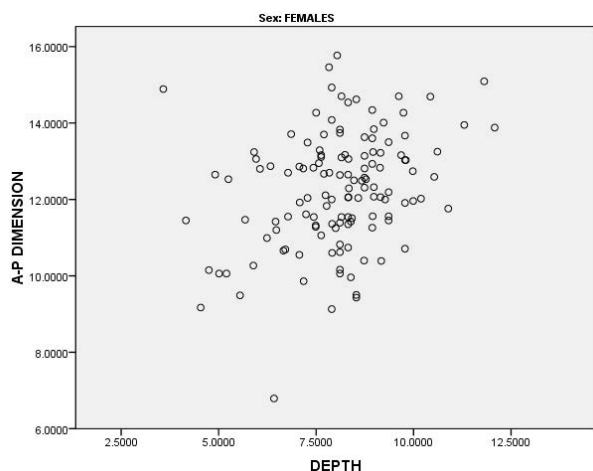
#### 4. Discussion

The present study intended to provide a novel insight into the morphometric characteristics of sella turcica. It is readily recognized on lateral cephalometric radiographs and routinely traced for cephalometric analysis. Beyond its anatomical importance, its morphometric characteristics were found to be highly variable. Axelsson et al. found gender differences in their study of the length and depth of sella turcica [7].

Previous studies have classified shape of sella subjectively, and variations were categorized into different types. Hence, many classifications are reported in the literature. Axelsson et al. performed an in-depth qualitative analysis of sella turcica considering their radiographic appearance, which made us to include his classification in our study.



**Figure 3-** Scatter Plot showing distribution of sella measurement (mm) in males.



**Figure 4-** Scatter Plot showing distribution of sella measurement (mm) in females.

Interestingly, Axelsson et al. found that less than 70% of their study sample had normal sella. The author believed that the remaining 30% of the study population was completely normal even though they failed to present with normal sella [7]. Similar results were observed in the present study where we observed normal sella in 70% of males and 67.7% of females. These results confirm that the shape of sella cannot be used as a reliable tool for evaluation of pathology. Exhaustive studies are required in this field to confirm the results.

According to the previously published data, the normal

vertical dimension of sella ranges from 4 to 12 mm and the antero-posterior dimension ranges from 5 to 16 mm [8, 9]. Similar results were observed in the present study. Many studies in the literature have documented the differences in linear measurements of sella in males and females [10-11]. Silverman et al. in their study on 320 radiographs concluded that males have larger sella turcica than females [6]. But in the present study, the mean A-P diameter and depth of sella was higher in females than males. This can be attributed to earlier onset and prolonged pre-pubertal growth spurts in females than males [11]. However, some studies proposed no significant difference in the measurements between males and females [12-14]. This can be attributed to differences in ethnic origin, which will have a definite influence on growth.

Our results confirmed the role of sella in sex determination. Hence discriminant analysis was done and an equation was derived. The measurements of sella were successful in identifying 58.5% of females and 57.7% of males with an overall accuracy rate of 58.1%. Though the accuracy rate was below standard, the results suggest that the measurements of sella can be used as an adjunct tool for sex determination.

**Table 1-** Distribution of observed sella shapes.

Sella shapes	Males	Females	Total	p-value
Normal	91 70.0%	88 67.7%	179 68.8%	0.306
Oblique Anterior	8 6.2%	17 13.1%	25 9.6%	
Shallow	21 16.2%	17 13.1%	38 14.6%	
Irregular	6 4.6%	3 2.3%	9 3.5%	
Pyramidal	4 3.1%	5 3.8%	9 3.5%	
Total	130 100.0%	130 100.0%	260 100.0%	

**Table 2-** Mean Scores of sella dimensions according to sex.

Sella shapes	Sex	n	Mean	S.D.	p-value
A-P Dimension (mm)	Males	130	11.74	1.73	0.01*
	Females	130	12.25	1.50	
Depth (mm)	Males	130	7.68	1.60	0.04*
	Females	130	8.08	1.49	

\*Statistically significant ( $P < 0.05$ )

**Table 3-** Intraclass Correlation.

Intraclass Correlation Coefficient for A-P Dimension					
Sella shapes	Intraclass Correlationa	95% C.I.		Cronbach's Alpha	p-value
		Lower Bound	Upper Bound		
Single Measures	0.993b	0.986	0.997	0.997	1.50
Average Measures	0.997c	0.993	0.998		1.60

Intraclass Correlation Coefficient for Depth					
Sella shapes	Intraclass Correlationa	95% C.I.		Cronbach's Alpha	p-value
		Lower Bound	Upper Bound		
Single Measures	0.998b	0.997	0.999	0.999	0.001*
Average Measures	0.999c	0.998	1.000		0.001*

C.I., Confidence Interval

**Table 4-** Wilk's Lambda Scores.

Sella dimensions	Wilks' Lambda	p-value
A-P Dimension	0.975	0.011*
Depth	0.984	0.040*

\*Statistically significant ( $p < 0.05$ )

## 5. Conclusion

The present study was the first of its kind in the South Indian population and is a useful initiative to use sella for sex determination. But it has to be noted that the degree of sexual dimorphism also varies with ethnic background, evolutionary changes and genetic influence. Further emphasis should be made in observing new parameters for

analyzing sella size and shape for improving the accuracy rate in gender determination. Hence, similar studies on large scale must be carried out in other regions to confirm these results.

### Conflict of interest

Authors declare no conflict of interest.

## References

1. Tekiner H, Acer N, Kelestimur F. Sella turcica: an anatomical, endocrinological, and historical perspective. *Pituitary* 2015; 18: 575-8.
2. Zagga AD, Ahmed H, Tadros AA, Saidu SA. Description of the normal variants of the anatomical shapes of the sella turcica using plain radiographs: experience



**Table 5-** Predicted Sex Determination.

Sex	Predicted Group Membership		
	Males	Females	Total
Males (n)	75	55	130
Males (%)	57.7%*	42.3%	100
Females (n)	54	76	130
Females (%)	41.5%	58.5%*	100
Function at group centroids	-0.174	0.174	Classified as male if $D < 0$ Classified as female if $D > 0$

\*58.1% of cases were classified correctly.

\*57.7% of males were classified correctly.58.5% of females were classified correctly.

**Table 6-** Sensitivity and specificity in identifying the correct gender using radiometric analysis of sella.

Sella dimensions	Percentage	95% C.I.
Sensitivity	49.6%	41.4% - 57.8%
Specificity	49.5%	39.8% - 59.2%
Positive Predictive Value	57.7	48.7% - 66.2%
Negative Predictive Value	41.5	33% - 50.51%

C.I., Confidence Interval

- from Sokoto, Northwestern Nigeria. *Ann Afr Med* 2008; 7: 77-81.
- Agrawal GN, Newton GB. Radiological Study of Normal Sella Turcica in Indians. *J Indian Med Assoc* 1968; 51: 319-23.
  - Taveras JM, Wood EH. *Diagnostic Radiology*. Second edition. The Williams Wilkins Company, Baltimore 1976; 1: 65-90.
  - Chavan SR, Kathole MA, Katti AS, Herekar NG. Radiological Analysis of Sella Turcica, *Int J Rec Trends Sci Technol* 2012; 4: 36-40.
  - Silverman FN. Roentgen standards for size of the pituitary fossa from infancy through adolescence. *Am J Roentgenol* 1957; 78: 451-60.
  - Axelsson S, Storhaug K, Kjaer I. Post-natal size and morphology of the sella turcica. Longitudinal cephalometric standards for Norwegians between 6 and 21 years of age. *Eur J Orthod* 2004; 26: 597-604.
  - Camp J. Normal and pathological anatomy of the sella turcica as revealed by roentgenograms. *Am J Roentgenol* 1924; 12: 143-55.
  - Chilton LA, Dorst JP, Garn SM. The volume of the sella turcica in children: new standards. *Am J Roentgenol* 1983; 140: 797-801.
  - Andredaki M, Koumantanou A, Dorotheou D, Halaizonetis DJ. A cephalometric morphometric study of the sella turcica. *Eur J Orthod* 2007; 29: 449-56.
  - Alkofide EA. The shape and size of the sella turcica in skeletal Class I, Class II, and Class III Saudi subjects. *Eur J Orthod* 2007; 29: 457-63.
  - Hasan HA, Alam MK, Yusof A, Mizushima H, Kida A, Osuga N. Size and Morphology of Sella Turcica in Malay populations: A 3D CT Study. *J Hard Tissue Biol* 2016; 25: 313-20.
  - Hasan HA, Alam MK, Abdullah YJ, Nakano J, Yusa T, Yusof A, et al. 3DCT Morphometric Analysis of Sella Turcica in Iraqi Population. *J Hard Tissue Biol* 2016; 25: 227-32.
  - Islam M, Alam MK, Yusof A, Kato I, Honda Y, Kubo K, et al. 3D CT Study of Morphological Shape and Size of Sella Turcica in Bangladeshi Population. *J Hard Tissue Biol* 2017; 26: 1-6.

