

جامعة نايف العربية للعلوم الأمنية
Naif Arab University for Security Sciences

Naif Arab University for Security Sciences
Arab Journal of Forensic Sciences & Forensic Medicine

www.nauss.edu.sa
http://ajfsfm.nauss.edu.sa



الجمعية العربية للعلوم الألة الجنائية والطب الشرعي
Arab Society for Forensic Sciences and Forensic Medicine

Lightning Skin Burns: A Case Report

حروق الجلد الناتجة عن صعقة البرق: تقرير حالة

Tarek Abdelraouf¹, Mohamed ElHafez¹, Ekramy Elmorsy^{2,*}

¹ Forensic Medicine Department, General Directorate of Health Affairs in the Northern Border Principality, Saudi Arabia

² Department of Pathology, Faculty of Medicine, Northern Border University, Arar, Saudi Arabia

Received 09 Nov. 2017; Accepted 15 Apr. 2018; Available Online 03 Jun. 2018



CrossMark

Abstract

Lightning strike is a rare natural phenomenon which can cause death due to serious medical complications including myocardial infarction, arrhythmia, cutaneous burns, and respiratory as well as neurological disorders. This study presents a report on a 50-year-old male who died after being struck by lightning. The man sustained burns from the neck to the ankle. Interestingly, fern-like skin erythema was seen in the anterior aspects of the right and left shoulders and left side of the lower part of the anterior abdominal wall. Multiple 2nd degree burns were found. The largest was found in the middle of the front of the neck extending to the upper part of the chest with linear extension to the front of the abdomen. Other burns were found in the abdominal wall, pubic region, and medial aspects of both thighs. Areas of erythema were found in the back of the left thigh and legs to the medial aspects of the ankles. Hair singing was found in the beard, back of both forearms and in the pubic region. Clothes were burnt and torn opposite to the skin lesions. The cause of death was most likely cardiorespiratory arrest. In conclusion, more awareness about lightning is highly recommended as it remains as a serious cause of environmental deaths with unique skin burns.

Keywords: Forensic Sciences, Lightning, Skin Burns, Fern-Like Skin Erythema, Electrocutation.

المستخلص

صعقة البرق هي ظاهرة طبيعية نادرة، والتي يمكن أن تسبب الموت بسبب مضاعفات طبية خطيرة بما في ذلك احتشاء عضلة القلب، وعدم انتظام ضربات القلب، والحروق الجلدية، واضطرابات الجهاز التنفسي، والاضطرابات العصبية.

تعرض هذه الدراسة حالة مقتل رجل يبلغ من العمر 50 عاماً أصيب بصعقة برق. ومن خلال فحص الجسم، كانت الحروق تملأ الجسم من الرقبة إلى كاحل القدم. ومن المثير للاهتمام، كان منظر الجلد المحمر الذي يبدو شكل السرخسيات في الجوانب الداخلية من الكتفين الأيمن والأيسر والجانب الأيسر من الجزء السفلي من جدار البطن الأمامي. تم العثور على حروق متعددة من الدرجة الثانية. والتي تم العثور على أكبرها في منتصف الجزء الأمامي من الرقبة وتمتد إلى الجزء العلوي من الصدر مع التمدد الخطي إلى الجزء الأمامي من البطن. كما عثر على حروق أخرى تمتد في جدار البطن، ومنطقة العانة، والجوانب الداخلية من كلا الفخذين. وكشف عن مناطق محمرة في الجزء الخلفي من الفخذ والساقين تمتد للجوانب الداخلية للكاحلين. تم العثور على شعر محروق في اللحية، والظهر من الساعدين وفي منطقة العانة. وقد حرقت الملابس وتمزقت في المناطق المتقابلة للإصابات الجلدية.

وكان سبب الوفاة على الأرجح هو التوقف القلبي الرئوي. وفي الختام، يُوصى بشدة بزيادة الوعي حول صعقات البرق لأنها تبقى سبباً خطيراً للوفيات البيئية مع حروق جلد فريدة.

الكلمات المفتاحية: علوم الأدلة الجنائية، البرق، حروق الجلد، الجلد المحمر الشبيه بالسرخسيات، الصعق بالكهرباء.



Production and hosting by NAUSS



* Corresponding Author: Ekramy Elmorsy

Email: ekramy_elmorsy@yahoo.com

doi: 10.26735/16586794.2018.015

1. Introduction

Lightning is a serious natural phenomenon that may cause damage and even death. Lightning is a sudden electrostatic discharge that occurs typically during a thunderstorm. This discharge occurs between electrically charged regions of a cloud, between two clouds, or between a cloud and the ground [1].

In the United States, 3,000 deaths and nearly 10,000 casualties caused by lightning were reported within the period from 1959-1994. This declined to less than 20 deaths in 2017, according to official statistics kept by the National Oceanic and Atmospheric Administration (NOAA). This was due to improved awareness and public education about lightning. However, the actual number of lightning casualties may be higher, as 50% of cases are unreported [2]. Lightning fatalities are more common in developing countries with more outdoor activities such as farming and tending animals. [3].

Direct strikes account for less than 5% of lightning deaths, while indirect mechanisms (contact, side flash, step voltage, or upward streamer) account for about 95% of cases. Lightning may first hit another object (eg, tree, tower, ground) with side flashes passing to a nearby person [4]. Lightning can cause fatal atrial and ventricular arrhythmias, myocardial injuries, and cardiac arrest. This may be due to direct depolarization of the myocardium or damage to the electrical systems of the heart and carotid bodies [5].

Skin burns are found in about 50% of victims. The energy from lightning flows through the person for a very short time, estimated to be a few nanoseconds, with the majority of its energy flashing around the body causing vaporization of sweat or rainwater with secondary steam burns, which are more evident than the other lightning burns caused by the direct heat of lightning [6,7].

Saudi Arabia has a desert climate except in the southwest, which shows features of semi-arid weather. It has high temperatures during the day and low temperatures at night with low incidence of lightning fatalities. This paper

reports a case of death due to lightning in the Northern Border province with different characteristic patterns of burns extending in the corpse in a cranio-caudal direction from the chin to the ankles.

2. Case Report

A 50-year-old male was found dead in the desert. His clothes were wet, burnt, torn and stripped off the body leaving it almost naked. Hair singeing was found in the beard, back of both forearms and in the pubic region (Figure-1).

Externally, there were multiple burns of different degrees distributed all over the body from the chin to the ankle in a cranio-caudal direction. Multiple second degree burns were found; the largest was found in the upper median part of the front of the chest against the upper, middle part of the sternum (5 x 15 cms dimensions) with two other symmetrical extensions from it to the upper part of the abdomen (Figure-2).

The right side of the abdomen showed two similar vertical second degree burns (Figure-2A and 2B), which ran from the level of the umbilicus and downwards to the pelvis and the upper part of the pubis. Another 2nd degree reddish burn (Figure-2C and 2E) with some denuded skin extended from the right side of the pelvis to the right thigh.

Erythema was noticed in the chest, abdomen, pelvis and lower limbs. It was parchment like, stiffened (leathery) or charred. Fern-like skin erythema (Figure- 2D) with its characteristic pattern was seen in the anterior aspects of the right and left shoulders in addition to the left side of the lower part of the anterior abdominal wall.

Areas of erythema were found in the lower limbs down to the ankle as follows: A reddish superficial burn, which extended mainly vertically in the lower half of the dorsal part of the left thigh, and the upper dorsal part of the left leg, with some denuded skin against the knee joint (Figure-3A). Another burn was found in the back of the right leg extending down to the back of the right ankle (Figure- 3B).

On internal examination, organs were congested with petechial hemorrhages in the white matter of the brain.



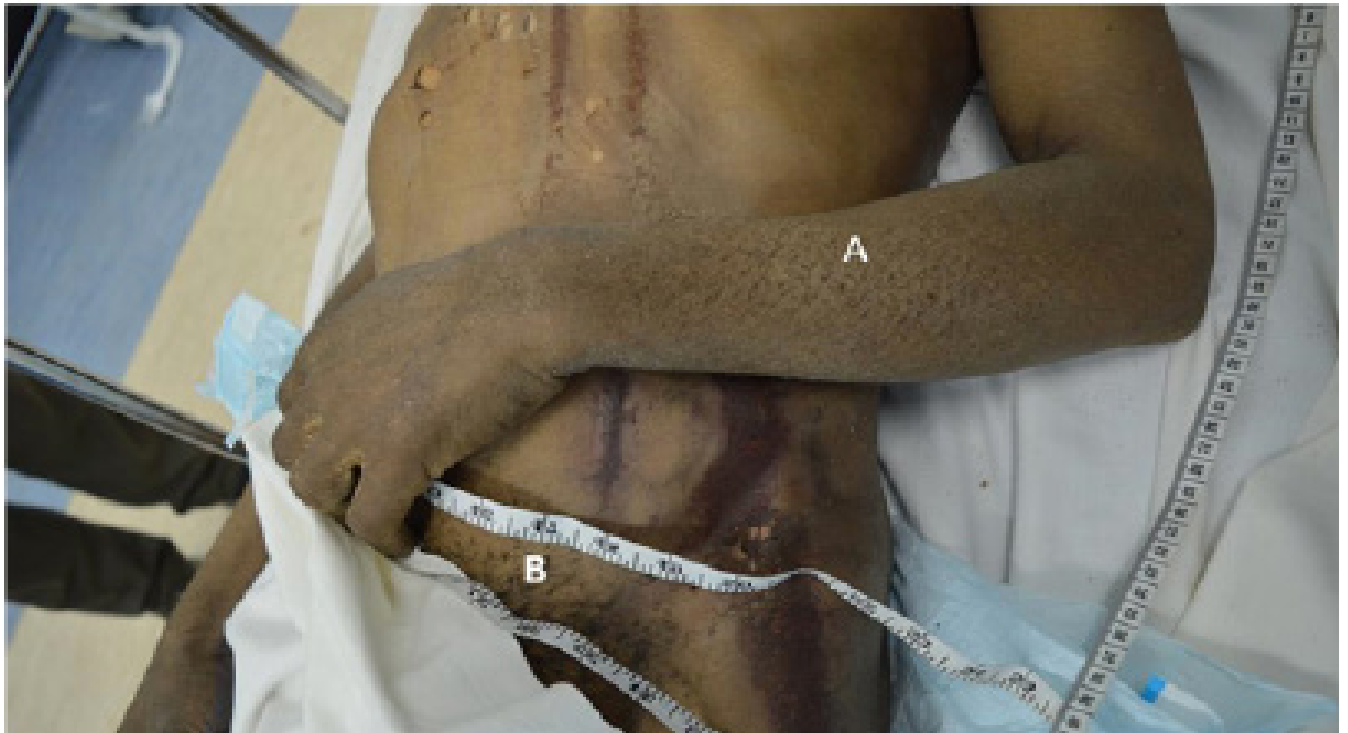

Figure 1- Singed hair on the back of the left forearm and in the pubic area caused by lightning strike.

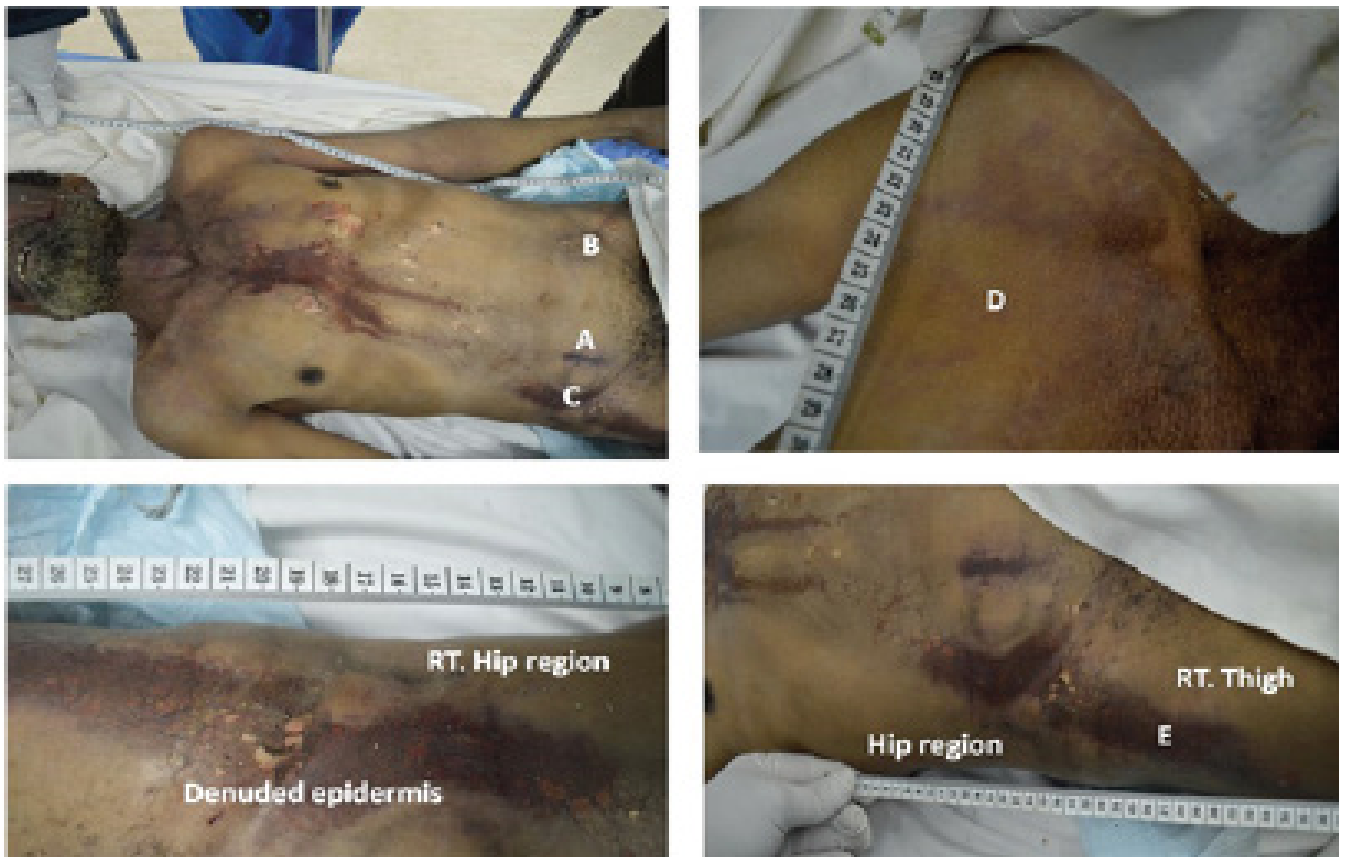

Figure 2- Multiple third degree skin burns due to lightning strikes. The largest one is seen in the middle of the front of the chest with 2 smaller radiating burns to the upper abdomen. A, B, C and E are degree burns in the lower abdomen and upper right thigh. D showing Fern sign area of erythema on the right shoulder.

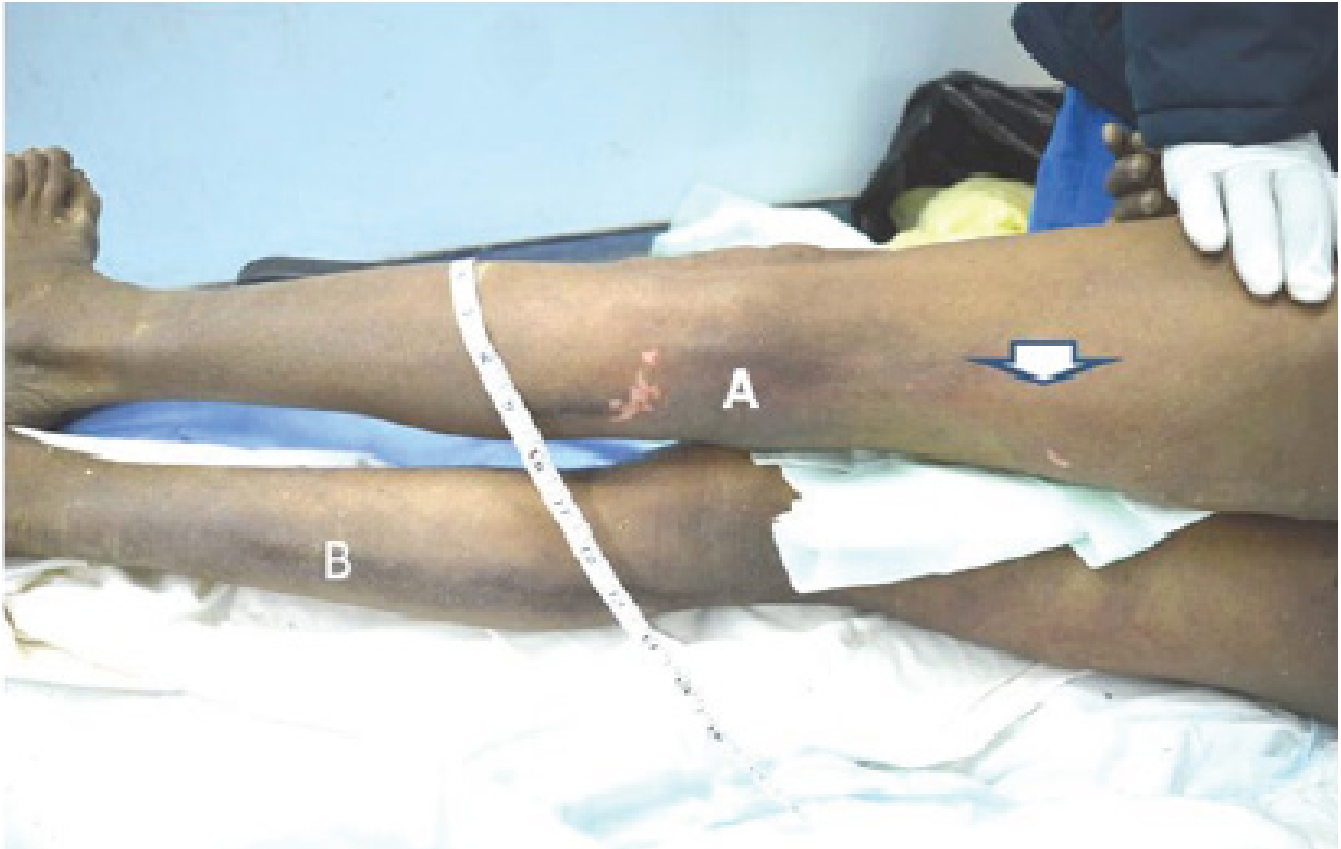


Figure 3- Lightning strike injuries in the lower limbs of the victim. Limbs showed a superficial burn, in the back of left thigh and leg with some denuded skin against the knee joint (A). The white arrow is pointing to its beginning. Another burn was found in the back of the right leg extending down to the back of the right ankle (B).

Lungs exuded bloody froth. Chest autopsy showed signs of surgical emphysema due to the effect of the lightning on the lung, which led to an escape of the air into the mediastinum and subcutaneous tissue. Histopathology revealed edematous lung tissue with exudations with ruptured marginal alveoli. Liver tissue also showed the expected post-mortem edematous and hemorrhagic changes with ballooned hepatocytes. Heart tissue did not show any specific histopathological findings. Overall, histopathological findings did not reveal a definite cause of death.

3. Discussion

The present work reports a case of death due to lightning in the Northern Border Province, Saudi Arabia. The victim's clothes were wet and burnt in addition to the skin injuries. The dead body showed first and second degree burns extending in a cranio-caudal direction from the

chin to the ankles. Fern sign erythema was found over the shoulders and abdomen. Singed hair was noticed in different parts of the body. The effect of lightning current on the heart rhythm could not be proved or disproved through the autopsy findings.

Lightning is a unidirectional massive current impulse to be clearly differentiated from direct or alternating current. Lightning occurs when the large potential difference between cloud and ground, measured in millions of volts, is broken down [8]. When coming into contact with the body, there is an enormous current flow through the body that lasts for a very short time. The majority of the lightning current is initially transmitted internally, after which the paths parallel to the skin surface break down. External flashes vaporize moisture on the skin and tear clothes, as seen in the present case [9].

Human injuries caused by lightning strike are clas-

sified according to one of five different mechanisms: direct strike, contact, side flash, and step voltage or upward streamer [10]. Lightning strikes can cause skin burns of 6 different types, which are feathering, linear, punctate, entry/exit, thermal contact, and flash burn. [11]. Fern signs or Lichtenberg burns with arborescent red areas of branching, and tree or fern-like patterns on the skin are highly characteristic of lightning [12]. A Lichtenberg burn is not a true burn as it is just an extravasation of red blood cells from ruptured capillaries due to electron showering over the skin [13].

Fern signs were faint in this victim due to his dark colored skin. The reason for the transient nature and exact mechanism is unknown [14]. In the current case, fern signs were found over the shoulders and the anterior abdominal wall. Although the temperatures associated with thermal injury are extremely high, the heat is rapidly dissipated and most resultant skin burns are superficial with little effect on deep tissue [15]. Although difficult to determine with certainty, injuries found in the current case were likely caused by a side flash mechanism, as the victim was mostly injured when charge from a nearby object or animal moved through the air to him. Other mechanisms are difficult to determine by analysis of the scene of death. In addition, absence of entry and exit wounds mostly exclude the direct strike as the main cause of death. In addition, erythema with some erosive lesions and denuded skin were scattered all over the body surface from the chin to the ankle with singed hair in different areas of the body, mainly in the pubis and over both forearms. Erythema seen in the current case was mainly steam burn due to steaming of the rainwater causing erythema with some areas of denuded skin.

Autopsy and histopathological evaluation revealed edematous lung with ruptured peripheral alveoli and pneumothorax, pneumo-mediastinum and surgical emphysema. Death was mostly caused by electrical disruption of the cardiac cycle, which shows negative autopsy data [16]. Pulmonary edema findings are also suggestive of heart failure as a terminal event. Pneumo-mediastinum was not the

cause of death as the lungs were not collapsed.

Finally, in spite of the media and public education about lightning, it is still one of the major causes of environmental deaths. Hence, more education and awareness programs should be planned and implemented. If the time between seeing lightning and hearing thunder is 30 seconds or shorter, persons must then expect that they are in real danger and should search for a shelter. Outdoor activities are better avoided within 30 minutes after the last seen lightning, even with clear sky and no rainfall [17]. In addition, it is also advisable to stay away from objects which conduct electricity such as barbed-wire fences, metal gates and bare electrical wires [18], and especially trees.

Funding

None.

Conflict of interest

None.

References

1. Rakov VA, Uman MA. Lightning: physics and effects. Cambridge University Press; 2003 Aug 4.
2. Holle RL, López RE, Howard KW, Vavrek J, Allsopp J. Safety in the presence of lightning. In Seminars in neurology. 1995; 15(4): 375-80
3. Holle RL. Annual rates of lightning fatalities by country. In Preprints of the International Lightning Detection Conference 2008 Apr 21 (pp. 21-23).
4. Cooper MA, Holle RL. Mechanisms of lightning injury should affect lightning safety messages. In 3rd International Lightning Meteorology Conference 2010 Apr 19 (pp. 19-22).
5. Sinha AK. Lightning-induced myocardial injury. A case report with management. Angiol. 1985;36(5):327-31. <https://doi.org/10.1177/000331978503600510>, PMID:4025941
6. Ohashi M, Kitagawa N, Ishikawa T. Lightning injury caused by discharges accompanying flash-



- overs—a clinical and experimental study of death and survival. *Burns*. 1986;12(7):496-501. [https://doi.org/10.1016/0305-4179\(86\)90076-8](https://doi.org/10.1016/0305-4179(86)90076-8)
7. Andrews CJ. Physical and medical effects of lightning on the human body. In: Cooray V, editor. *The lightning flash*. London UK: IEE Press; 2004
 8. Cooper MA. Emergent care of lightning and electrical injuries. In *Seminars in neurology* 1995 Sep (Vol. 15, No. 3, pp. 268-278).
 9. Jex-Blake AJ. The Goulstonian Lectures on death by electric currents and by lightning: delivered before the Royal College of Physicians of London. *British medical journal*. 1913;1(2723):492. <https://doi.org/10.1136/bmj.1.2723.492>, PMID:20766541 PMCID:PMC2298678
 10. Cooper MA. A fifth mechanism of lightning injury. *Acad Emerg Med*. 2002;9(2):172-4. <https://doi.org/10.1111/j.1553-2712.2002.tb00237.x>, PMID:11825846
 11. Ten Duis HJ, Klasen HJ, Nijsten MW, Pietronero L. Superficial lightning injuries—their ‘fractal’ shape and origin. *Burns*. 1987;13(2):141-6. [https://doi.org/10.1016/0305-4179\(87\)90104-5](https://doi.org/10.1016/0305-4179(87)90104-5)
 12. Kreci A, Vyshka G, Sinamati A. Lightning injuries in an in-door setting: a case report and review of the literature. *Int J Environ Res Public Health*. 2013;1(2):16-20.
 13. Cooper M. et al. Blumenthal R: *Lightning Injuries*. Au-erbach PS ed: *Wilderness Medicine*, 6th ed. Philadelphia: Elsevier/Mosby; 2012.
 14. Sumangala CN, Kumar MP. Lightning death: a case report. *J Indian Acad Forensic Med*. 2015;37(1):93-5. <https://doi.org/10.5958/0974-0848.2015.00023.8>
 15. Blount BW. Lightning injuries. *Am Fam Physician*. 1990;42(2):405-15. PMID:2200249
 16. Cohle SD, Sampson BA. The negative autopsy: sudden cardiac death or other?. *Cardiovasc Pathol*. 2001;10(5):219-22. [https://doi.org/10.1016/S1054-8807\(01\)00093-X](https://doi.org/10.1016/S1054-8807(01)00093-X)
 17. Gatewood MO, Zane RD. Lightning injuries. *Emerg Med Clin North Am*. 2004;22(2):369-403. <https://doi.org/10.1016/j.emc.2004.02.002>, PMID:15163573
 18. Zimmermann C, Cooper MA, Holle RL. Lightning safety guidelines. *Ann Emerg Med*. 2002;39(6):A1. <https://doi.org/10.1067/mem.2002.124439>

